

**Honors Anatomy & Physiology
Summer Work
2023-2024**


The purpose of this summer work is to provide an introduction to Anatomy & Physiology prior to the start of the school year. Please complete the following before the first day of school.


1. Read Chapter 1 (attached PDF) and complete the Study Guide (attached PDF) ***due the first day of school.***
2. Purchase a 1" 3-ring binder, notebook paper and a package of divider tabs (you will need a total of 12 divider tabs). This will be for notes, worksheets, etc.
3. Join the appropriate Google Classroom site for the course:
 - a. Honors A&P (*Advancement to Nursing students only!*) Join code = **5or3lsk**.
 - OR-
 - b. Honors A&P (if not in nursing): Join code = **ehromnk**.

Be prepared to be evaluated on the information shortly after your arrival to school in the fall. If you have any questions you may email me over the summer imonk@barbertonschools.org.

We look forward to having you in Anatomy & Physiology next year!

Mrs. Monk & Skully





1

The Human Body: An Orientation

An Overview of Anatomy and Physiology (pp. 2–3)

Topics of Anatomy (p. 2)

Topics of Physiology (pp. 2–3)

Complementarity of Structure and Function (p. 3)

Levels of Structural Organization (pp. 3–4)

Maintaining Life (pp. 4–8)

Necessary Life Functions (pp. 4–8)

Survival Needs (p. 8)

Homeostasis (pp. 8–11)

Homeostatic Control (pp. 9–11)

Homeostatic Imbalance (p. 11)

The Language of Anatomy (pp. 11–20)

Anatomical Position and Directional Terms (pp. 11–13)

Regional Terms (p. 13)

Anatomical Variability (p. 14)

Body Planes and Sections (p. 14)

Body Cavities and Membranes (pp. 14–20)

Welcome to the study of one of the most fascinating subjects possible—your own body. Such a study is not only highly personal, but timely as well. We get news of some medical advance almost daily. To appreciate emerging discoveries in genetic engineering, to understand new techniques for detecting and treating disease, and to make use of published facts on how to stay healthy, you'll find it helpful to learn about the workings of your body. If you are preparing for a career in the health sciences, the study of anatomy and physiology has added rewards because it provides the foundation needed to support your clinical experiences.

In this chapter we define and contrast anatomy and physiology and discuss how the human body is organized. Then we review needs and functional processes common to all living organisms. Three essential concepts—the *complementarity of structure and function*,

the hierarchy of structural organization, and homeostasis—will unify and form the bedrock for your study of the human body. The final section of the chapter deals with the language of anatomy—terminology that anatomists use to describe the body or its parts.

An Overview of Anatomy and Physiology

- ✓ Define anatomy and physiology and describe their subdivisions.
- ✓ Explain the principle of complementarity.

Two complementary branches of science—**anatomy** and **physiology**—provide the concepts that help us to understand the human body. **Anatomy** studies the *structure* of body parts and their relationships to one another. Anatomy has a certain appeal because it is concrete. Body structures can be seen, felt, and examined closely. You don't need to imagine what they look like.

Physiology concerns the *function* of the body, in other words, how the body parts work and carry out their life-sustaining activities. When all is said and done, physiology is explainable only in terms of the underlying anatomy.

To simplify the study of the body, when we refer to body structures and/or physiological values (body temperature, heart rate, and the like), we will assume that we are talking about a healthy young (22-year-old) male weighing about 155 lb (the *reference man*) or a healthy young female weighing about 125 lb (the *reference woman*).

Topics of Anatomy

Anatomy is a broad field with many subdivisions, each providing enough information to be a course in itself. **Gross**, or **macroscopic anatomy** is the study of large body structures visible to the naked eye, such as the heart, lungs, and kidneys. Indeed, the term *anatomy* (derived from the Greek words meaning “to cut apart”) relates most closely to gross anatomy because in such studies preserved animals or their organs are dissected (cut up) to be examined.

Gross anatomy can be approached in different ways. In **regional anatomy**, all the structures (muscles, bones, blood vessels, nerves, etc.) in a particular region of the body, such as the abdomen or leg, are examined at the same time.

In **systemic anatomy** (sis-tem'ik),* body structure is studied system by system. For example, when studying the cardiovascular system, you would examine the heart and the blood vessels of the entire body.

Another subdivision of gross anatomy is **surface anatomy**, the study of internal structures as they relate to the overlying skin surface. You use surface anatomy when you identify the

bulging muscles beneath a bodybuilder's skin, and clinicians use it to locate appropriate blood vessels in which to feel pulses and draw blood.

Microscopic anatomy deals with structures too small to be seen with the naked eye. For most such studies, exceedingly thin slices of body tissues are stained and mounted on glass slides to be examined under the microscope. Subdivisions of microscopic anatomy include **cytology** (si-tol'o-je), which considers the cells of the body, and **histology** (his-tol'o-je), the study of tissues.

Developmental anatomy traces structural changes that occur in the body throughout the life span. **Embryology** (em'bre-ol'o-je), a subdivision of developmental anatomy, concerns developmental changes that occur before birth.

Some highly specialized branches of anatomy are used primarily for medical diagnosis and scientific research. For example, **pathological anatomy** studies structural changes caused by disease. **Radiographic anatomy** studies internal structures as visualized by X-ray images or specialized scanning procedures.

Subjects of interest to anatomists range from easily seen structures down to the smallest molecule. In **molecular biology**, for example, the structure of biological molecules (chemical substances) is investigated. Molecular biology is actually a separate branch of biology, but it falls under the anatomy umbrella when we push anatomical studies to the subcellular level.

One essential tool for studying anatomy is a mastery of anatomical terminology. Others are observation, manipulation, and, in a living person, **palpation** (feeling organs with your hands) and **auscultation** (listening to organ sounds with a stethoscope). A simple example illustrates how some of these tools work together in an anatomical study.

Let's assume that your topic is freely movable joints of the body. In the laboratory, you will be able to *observe* an animal joint, noting how its parts fit together. You can work the joint (*manipulate* it) to determine its range of motion. Using *anatomical terminology*, you can name its parts and describe how they are related so that other students (and your instructor) will have no trouble understanding you. The list of word roots (at the back of the book) and the glossary will help you with this special vocabulary.

Although you will make most of your observations with the naked eye or with the help of a microscope, medical technology has developed a number of sophisticated tools that can peer into the body without disrupting it. Read about these exciting medical imaging techniques in *A Closer Look* on pp. 16–17.

Topics of Physiology

Like anatomy, physiology has many subdivisions. Most of them consider the operation of specific organ systems. For example, **renal physiology** concerns kidney function and urine production. **Neurophysiology** explains the workings of the nervous system. **Cardiovascular physiology** examines the operation of the heart and blood vessels. While

*For the pronunciation guide rules, see the first page of the glossary in the back of the book.

anatomy provides us with a static image of the body's architecture, physiology reveals the body's dynamic and animated workings.

Physiology often focuses on events at the cellular or molecular level. This is because the body's abilities depend on those of its individual cells, and cells' abilities ultimately depend on the chemical reactions that go on within them. Physiology also rests on principles of physics, which help to explain electrical currents, blood pressure, and the way muscles use bones to cause body movements, among other things. We present basic chemical and physical principles in Chapter 2 and throughout the book as needed to explain physiological topics.

Complementarity of Structure and Function

Although it is possible to study anatomy and physiology individually, they are really inseparable because function always reflects structure. That is, what a structure can do depends on its specific form. This key concept is called the **principle of complementarity of structure and function**.

For example, bones can support and protect body organs because they contain hard mineral deposits. Blood flows in one direction through the heart because the heart has valves that prevent backflow. Throughout this book, we accompany a description of a structure's anatomy with an explanation of its function, and we emphasize structural characteristics contributing to that function.

☒ Check Your Understanding

1. In what way does physiology depend on anatomy?
2. Would you be studying anatomy or physiology if you investigated how muscles shorten? If you explored the location of the lungs in the body?

For answers, see Appendix H.

Levels of Structural Organization

- ✓ Name the different levels of structural organization that make up the human body, and explain their relationships.
- ✓ List the 11 organ systems of the body, identify their components, and briefly explain the major function(s) of each system.

The human body has many levels of structural organization (**Figure 1.1**). The simplest level of the structural hierarchy is the **chemical level**, which we study in Chapter 2. At this level, *atoms*, tiny building blocks of matter, combine to form *molecules* such as water and proteins. Molecules, in turn, associate in specific ways to form *organelles*, basic components of the microscopic cells. *Cells* are the smallest units of living things. We examine the **cellular level** in Chapter 3. All

cells have some common functions, but individual cells vary widely in size and shape, reflecting their unique functions in the body.

The simplest living creatures are single cells, but in complex organisms such as human beings, the hierarchy continues on to the **tissue level**. *Tissues* are groups of similar cells that have a common function. The four basic tissue types in the human body are epithelium, muscle, connective tissue, and nervous tissue.

Each tissue type has a characteristic role in the body, which we explore in Chapter 4. Briefly, epithelium covers the body surface and lines its cavities. Muscle provides movement. Connective tissue supports and protects body organs. Nervous tissue provides a means of rapid internal communication by transmitting electrical impulses.

An *organ* is a discrete structure composed of at least two tissue types (four is more common) that performs a specific function for the body. The liver, the brain, and a blood vessel are very different from the stomach, but each is an organ. You can think of each organ of the body as a specialized functional center responsible for a necessary activity that no other organ can perform.

At the **organ level**, extremely complex functions become possible. Let's take the stomach for an example. Its lining is an epithelium that produces digestive juices. The bulk of its wall is muscle, which churns and mixes stomach contents (food). Its connective tissue reinforces the soft muscular walls. Its nerve fibers increase digestive activity by stimulating the muscle to contract more vigorously and the glands to secrete more digestive juices.

The next level of organization is the **organ system level**. Organs that work together to accomplish a common purpose make up an *organ system*. For example, the heart and blood vessels of the cardiovascular system circulate blood continuously to carry oxygen and nutrients to all body cells. Besides the cardiovascular system, the other organ systems of the body are the integumentary, skeletal, muscular, nervous, endocrine, lymphatic, respiratory, digestive, urinary, and reproductive systems. (Note that the immune system is closely associated with the lymphatic system.) Look ahead to Figure 1.3 on pp. 6 and 7 for an overview of the 11 organ systems, which we discuss in the next section and study in more detail in Units 2–5.

The highest level of organization is the *organism*, the living human being. The **organismal level** represents the sum total of all structural levels working together to keep us alive.

☒ Check Your Understanding

3. What level of structural organization is typical of a cytologist's field of study?
4. What is the correct structural order for the following terms: tissue, organism, organ, cell?
5. Which organ system includes the bones and cartilages? Which includes the nasal cavity, lungs, and trachea?

For answers, see Appendix H.

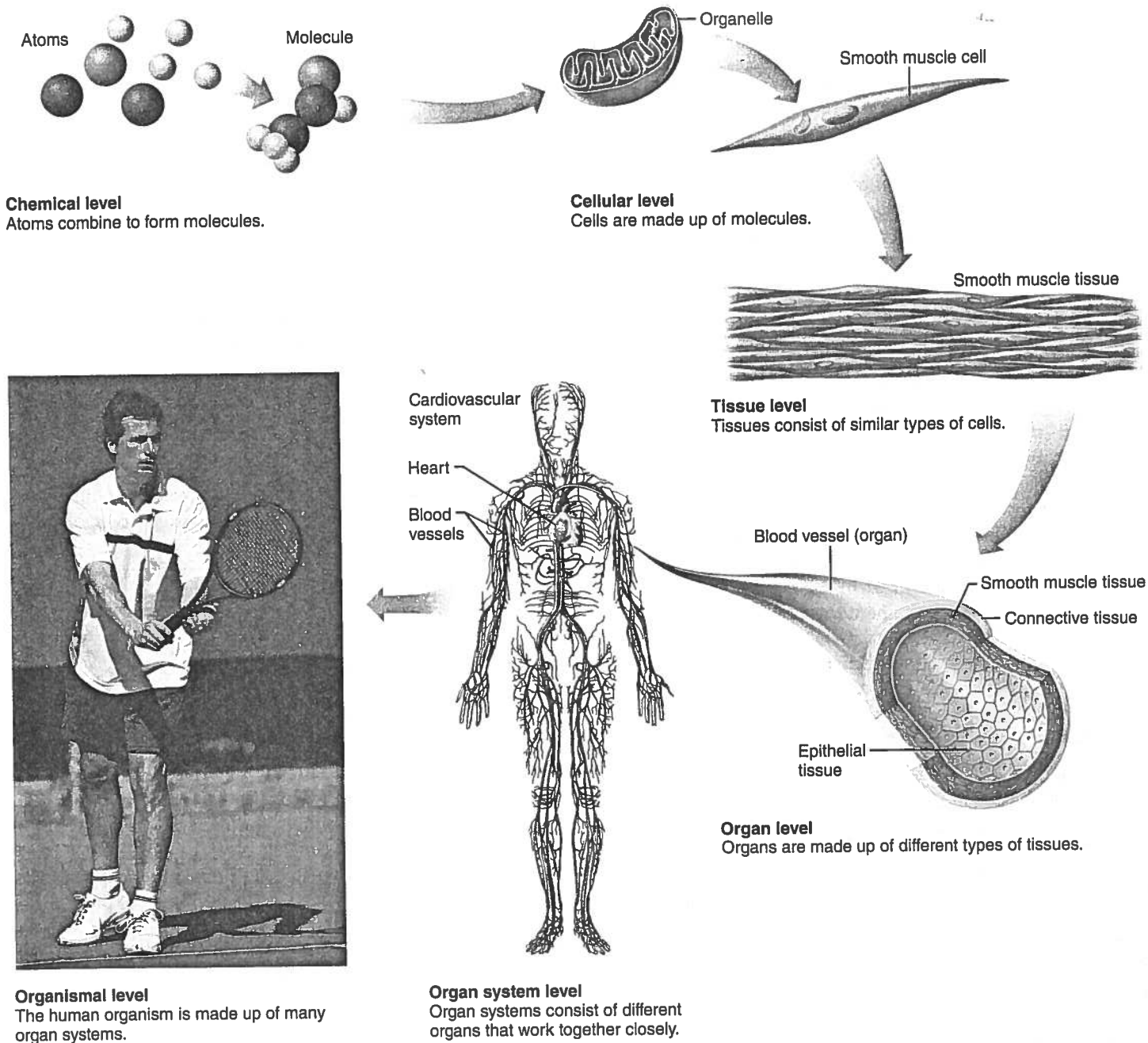


Figure 1.1 Levels of structural organization. Components of the cardiovascular system are used to illustrate the levels of structural organization in a human being.

Maintaining Life

- ✓ List the functional characteristics necessary to maintain life in humans.
- ✓ List the survival needs of the body.

Necessary Life Functions

Now that you know the structural levels of the human body, the question that naturally follows is: What does this highly organized human body do?

Like all complex animals, humans maintain their boundaries, move, respond to environmental changes, take in and digest nutrients, carry out metabolism, dispose of wastes, reproduce themselves, and grow. We will introduce these necessary life functions here and discuss them in more detail in later chapters.

We cannot emphasize too strongly that all body cells are interdependent. This interdependence is due to the fact that humans are multicellular organisms and our vital body functions are parceled out among different organ systems. Organ systems, in turn, work cooperatively to promote the well-being

of the entire body. This theme is repeated throughout the book. **Figure 1.2** identifies some of the organ systems making major contributions to necessary life functions. Also, as you read this section, check **Figure 1.3** for more detailed descriptions of the body's organ systems.

Maintaining Boundaries

Every living organism must **maintain its boundaries** so that its internal environment (its inside) remains distinct from the external environment surrounding it (its outside). In single-celled organisms, the external boundary is a limiting membrane that encloses its contents and lets in needed substances while restricting entry of potentially damaging or unnecessary substances. Similarly, all the cells of our body are surrounded by a selectively permeable membrane.

Additionally, the body as a whole is enclosed and protected by the integumentary system, or skin (Figure 1.3a). This system protects our internal organs from drying out (a fatal change), bacteria, and the damaging effects of heat, sunlight, and an unbelievable number of chemicals in the external environment.

Movement

Movement includes the activities promoted by the muscular system, such as propelling ourselves from one place to another by running or swimming, and manipulating the external environment with our nimble fingers (Figure 1.3c). The skeletal system provides the bony framework that the muscles pull on as they work (Figure 1.3b). Movement also occurs when substances such as blood, foodstuffs, and urine are propelled through internal organs of the cardiovascular, digestive, and urinary systems, respectively. On the cellular level, the muscle cell's ability to move by shortening is more precisely called **contractility**.

Responsiveness

Responsiveness, or **excitability**, is the ability to sense changes (which serve as stimuli) in the environment and then respond to them. For example, if you cut your hand on broken glass, a withdrawal reflex occurs—you involuntarily pull your hand away from the painful stimulus (the broken glass). You don't have to think about it—it just happens! Likewise, when carbon dioxide in your blood rises to dangerously high levels, chemical sensors respond by sending messages to brain centers controlling respiration, and you breathe more rapidly.

Because nerve cells are highly excitable and communicate rapidly with each other via electrical impulses, the nervous system is most involved with responsiveness (Figure 1.3d). However, all body cells are excitable to some extent.

Digestion

Digestion is the breaking down of ingested foodstuffs to simple molecules that can be absorbed into the blood. The nutrient-rich blood is then distributed to all body cells by the cardiovascular system. In a simple, one-celled organism such as an amoeba,

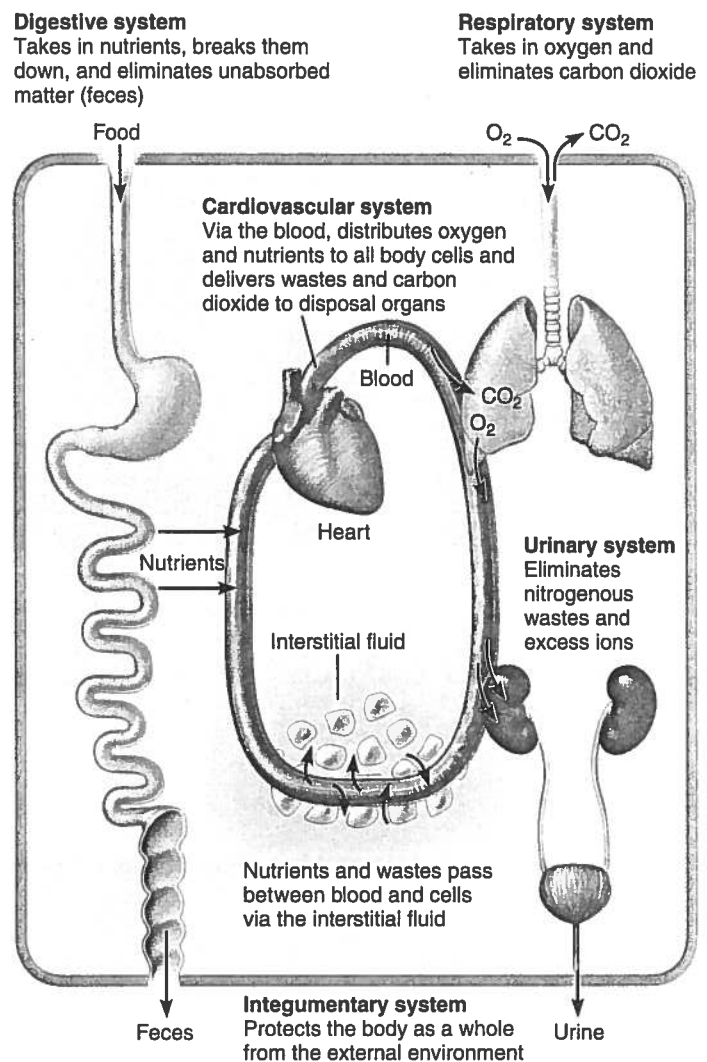
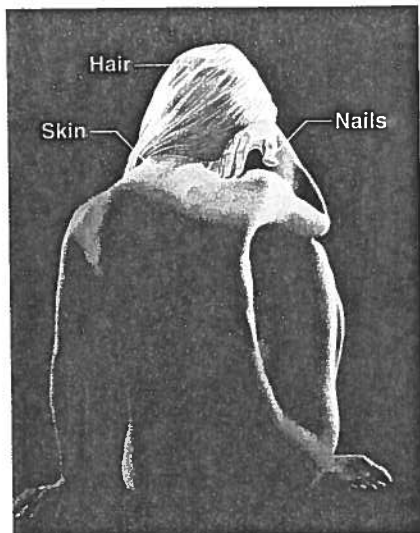


Figure 1.2 Examples of interrelationships among body organ systems.

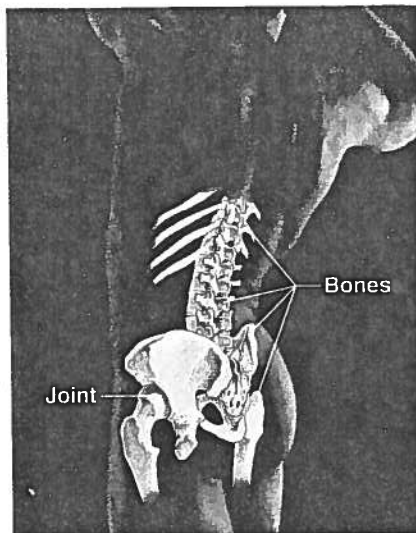
the cell itself is the “digestion factory,” but in the multicellular human body, the digestive system performs this function for the entire body (Figure 1.3i).

Metabolism

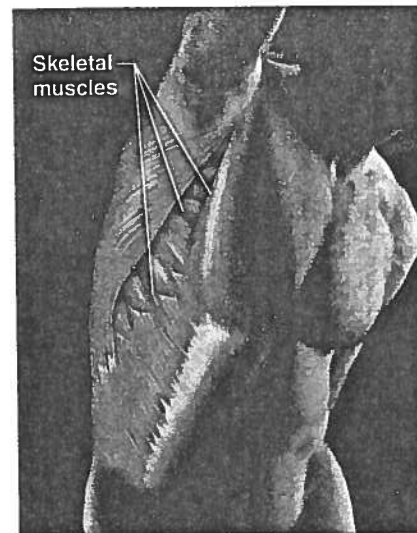
Metabolism (mĕ-tab’o-lizm; “a state of change”) is a broad term that includes all chemical reactions that occur within body cells. It includes breaking down substances into their simpler building blocks (more specifically, the process of *catabolism*), synthesizing more complex cellular structures from simpler substances (*anabolism*), and using nutrients and oxygen to produce (via *cellular respiration*) ATP, the energy-rich molecules that power cellular activities. Metabolism depends on the digestive and respiratory systems to make nutrients and oxygen available to the blood and on the cardiovascular system to distribute them throughout the body (Figure 1.3i, h, and f, respectively). Metabolism is regulated largely by hormones secreted by endocrine system glands (Figure 1.3e).

**(a) Integumentary System**

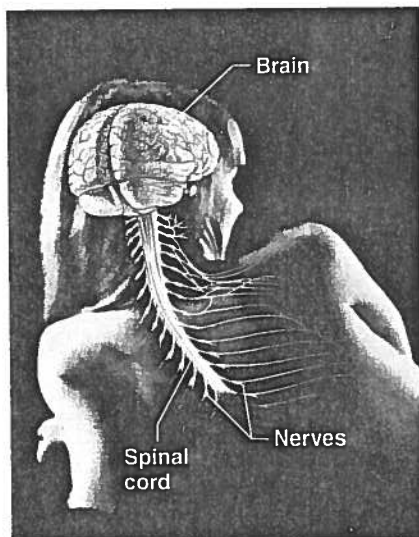
Forms the external body covering, and protects deeper tissues from injury. Synthesizes vitamin D, and houses cutaneous (pain, pressure, etc.) receptors and sweat and oil glands.

**(b) Skeletal System**

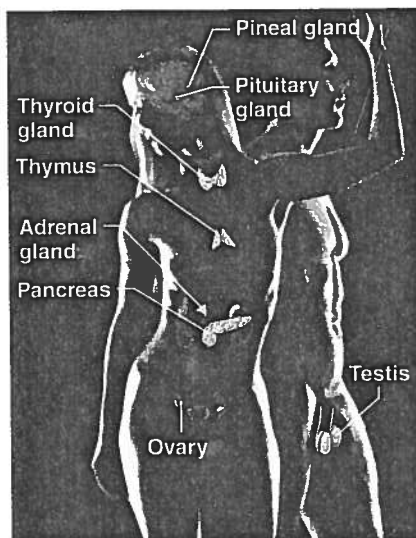
Protects and supports body organs, and provides a framework the muscles use to cause movement. Blood cells are formed within bones. Bones store minerals.

**(c) Muscular System**

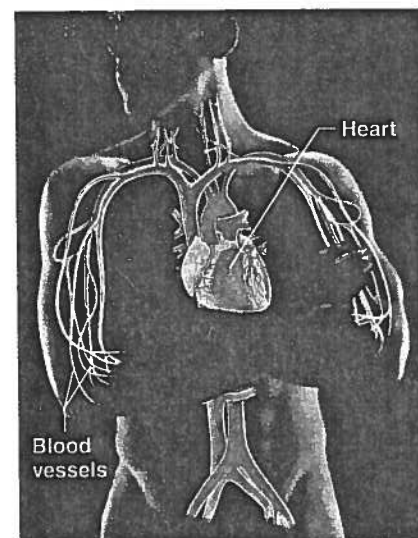
Allows manipulation of the environment, locomotion, and facial expression. Maintains posture, and produces heat.

**(d) Nervous System**

As the fast-acting control system of the body, it responds to internal and external changes by activating appropriate muscles and glands.

**(e) Endocrine System**

Glands secrete hormones that regulate processes such as growth, reproduction, and nutrient use (metabolism) by body cells.

**(f) Cardiovascular System**

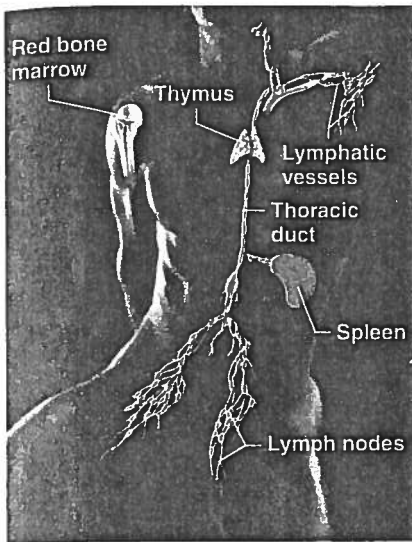
Blood vessels transport blood, which carries oxygen, carbon dioxide, nutrients, wastes, etc. The heart pumps blood.

Figure 1.3 The body's organ systems and their major functions.

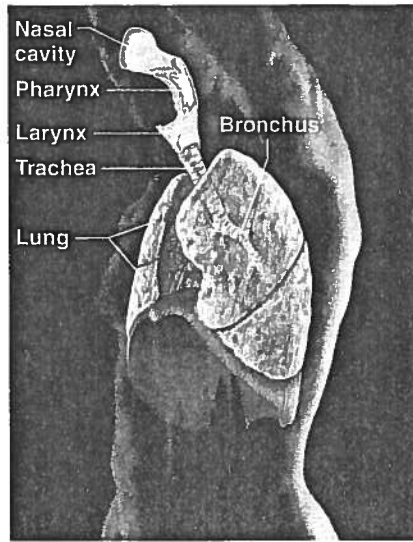
Excretion

Excretion is the process of removing wastes, or *excreta* (ek-skre'tah), from the body. If the body is to operate as we expect it to, it must get rid of nonuseful substances produced during digestion and metabolism.

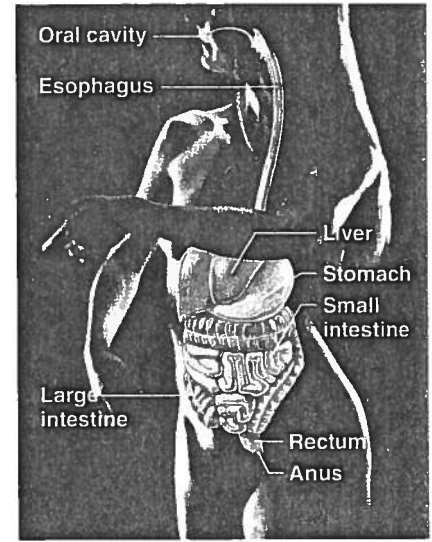
Several organ systems participate in excretion. For example, the digestive system rids the body of indigestible food residues in feces, and the urinary system disposes of nitrogen-containing metabolic wastes, such as urea, in urine (Figure 1.3i and j). Carbon dioxide, a by-product of cellular respiration, is carried in



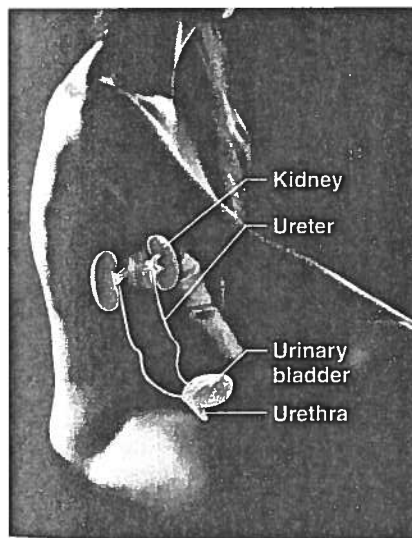
(g) Lymphatic System/Immunity
Picks up fluid leaked from blood vessels and returns it to blood. Disposes of debris in the lymphatic stream. Houses white blood cells (lymphocytes) involved in immunity. The immune response mounts the attack against foreign substances within the body.



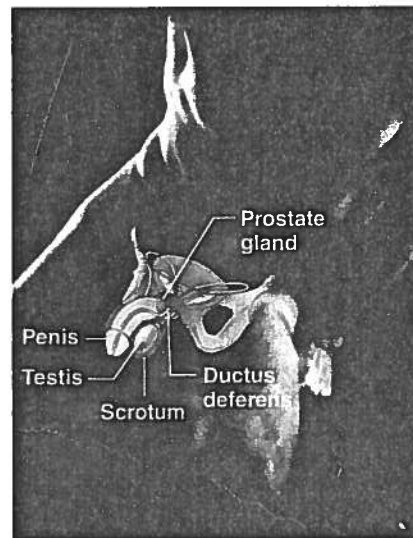
(h) Respiratory System
Keeps blood constantly supplied with oxygen and removes carbon dioxide. The gaseous exchanges occur through the walls of the air sacs of the lungs.



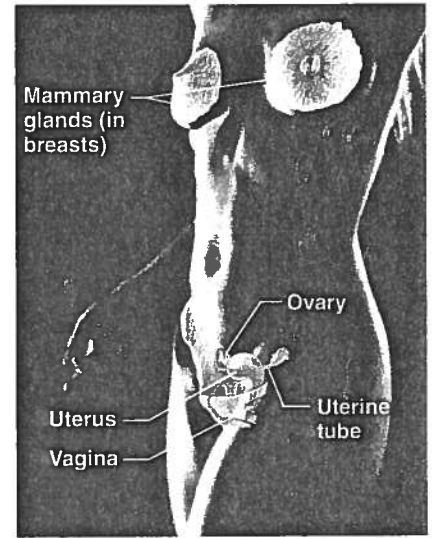
(i) Digestive System
Breaks down food into absorbable units that enter the blood for distribution to body cells. Indigestible foodstuffs are eliminated as feces.



(j) Urinary System
Eliminates nitrogenous wastes from the body. Regulates water, electrolyte and acid-base balance of the blood.



(k) Male Reproductive System
Overall function is production of offspring. Testes produce sperm and male sex hormone, and male ducts and glands aid in delivery of sperm to the female reproductive tract. Ovaries produce eggs and female sex hormones. The remaining female structures serve as sites for fertilization and development of the fetus. Mammary glands of female breasts produce milk to nourish the newborn.



(l) Female Reproductive System
Overall function is production of offspring. Testes produce sperm and male sex hormone, and male ducts and glands aid in delivery of sperm to the female reproductive tract. Ovaries produce eggs and female sex hormones. The remaining female structures serve as sites for fertilization and development of the fetus. Mammary glands of female breasts produce milk to nourish the newborn.

the blood to the lungs, where it leaves the body in exhaled air (Figure 1.3h).

Reproduction

Reproduction occurs at the cellular and the organismal level. In cellular reproduction, the original cell divides, producing two identical daughter cells that may then be used for body growth

or repair. Reproduction of the human organism, or making a whole new person, is the major task of the reproductive system. When a sperm unites with an egg, a fertilized egg forms and develops into a baby within the mother's body. The reproductive system is directly responsible for producing offspring, but its function is exquisitely regulated by hormones of the endocrine system (Figure 1.3e).

Because males produce sperm and females produce eggs (ova), there is a division of labor in reproduction, and the reproductive organs of males and females are different (Figure 1.3k, l). Additionally, the female's reproductive structures provide the site for fertilization of eggs by sperm, and then protect and nurture the developing fetus until birth.

Growth

Growth is an increase in size of a body part or the organism as a whole. It is usually accomplished by increasing the number of cells. However, individual cells also increase in size when not dividing. For true growth to occur, constructive activities must occur at a faster rate than destructive ones.

Survival Needs

The ultimate goal of all body systems is to maintain life. However, life is extraordinarily fragile and requires several factors. These factors, which we will call *survival needs*, include nutrients (food), oxygen, water, and appropriate temperature and atmospheric pressure.

Nutrients

Nutrients, taken in via the diet, contain the chemical substances used for energy and cell building. Most plant-derived foods are rich in carbohydrates, vitamins, and minerals, whereas most animal foods are richer in proteins and fats.

Carbohydrates are the major energy fuel for body cells. Proteins, and to a lesser extent fats, are essential for building cell structures. Fats also provide a reserve of energy-rich fuel. Selected minerals and vitamins are required for the chemical reactions that go on in cells and for oxygen transport in the blood. The mineral calcium helps to make bones hard and is required for blood clotting.

Oxygen

All the nutrients in the world are useless unless **oxygen** is also available. Because the chemical reactions that release energy from foods are *oxidative* reactions that require oxygen, human cells can survive for only a few minutes without oxygen. Approximately 20% of the air we breathe is oxygen. The cooperative efforts of the respiratory and cardiovascular systems make oxygen available to the blood and body cells.

Water

Water accounts for 60–80% of our body weight and is the single most abundant chemical substance in the body. It provides the watery environment necessary for chemical reactions and the fluid base for body secretions and excretions. We obtain water chiefly from ingested foods or liquids. We lose it from the body by evaporation from the lungs and skin and in body excretions.

Normal Body Temperature

If chemical reactions are to continue at life-sustaining rates, **normal body temperature** must be maintained. As body temperature drops below 37°C (98.6°F), metabolic reactions become

slower and slower, and finally stop. When body temperature is too high, chemical reactions occur at a frantic pace and body proteins lose their characteristic shape and stop functioning. At either extreme, death occurs. The activity of the muscular system generates most body heat.

Appropriate Atmospheric Pressure

Atmospheric pressure is the force that air exerts on the surface of the body. Breathing and gas exchange in the lungs depend on *appropriate* atmospheric pressure. At high altitudes, where atmospheric pressure is lower and the air is thin, gas exchange may be inadequate to support cellular metabolism.



The mere presence of these survival factors is not sufficient to sustain life. They must be present in *appropriate* amounts. Too much and too little may be equally harmful. For example, oxygen is essential, but excessive amounts are toxic to body cells. Similarly, the food we eat must be of high quality and in proper amounts. Otherwise, nutritional disease, obesity, or starvation is likely. Also, while the needs listed above are the most crucial, they do not even begin to encompass all of the body's needs. For example, we can live without gravity if we must, but the quality of life suffers.

✓ Check Your Understanding

- What separates living beings from nonliving objects?
- What name is given to all chemical reactions that occur within body cells?
- Why is it necessary to be in a pressurized cabin when flying at 30,000 feet?

For answers, see Appendix H.

Homeostasis

- ✓ Define homeostasis and explain its significance.
- ✓ Describe how negative and positive feedback maintain body homeostasis.
- ✓ Describe the relationship between homeostatic imbalance and disease.

When you think about the fact that your body contains trillions of cells in nearly constant activity, and that remarkably little usually goes wrong with it, you begin to appreciate what a marvelous machine your body is. Walter Cannon, an American physiologist of the early twentieth century, spoke of the “wisdom of the body,” and he coined the word **homeostasis** (ho’me-o-sta’sis) to describe its ability to maintain relatively stable internal conditions even though the outside world changes continuously.

Although the literal translation of homeostasis is “unchanging,” the term does not really mean a static, or unchanging, state. Rather, it indicates a *dynamic* state of equilibrium, or a balance, in which internal conditions vary, but always within relatively

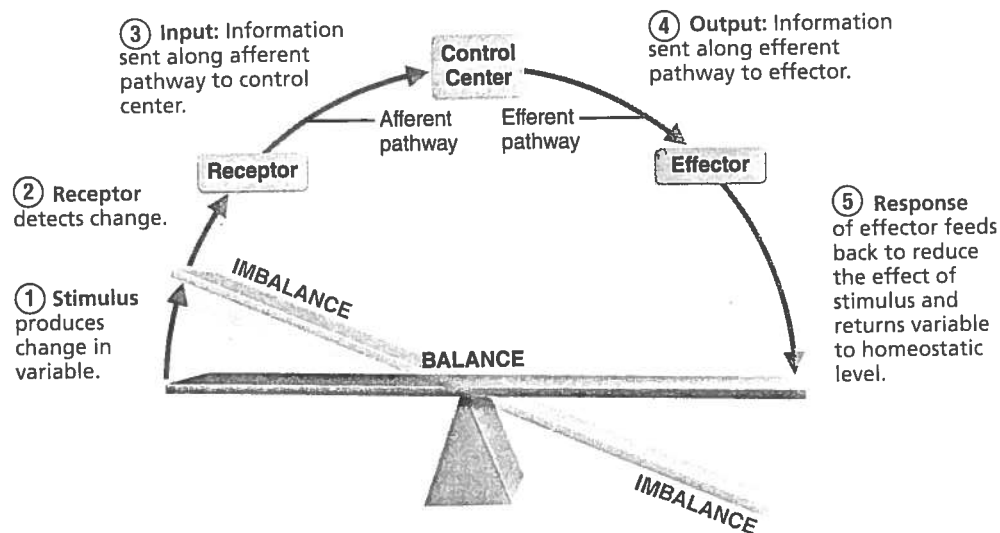


Figure 1.4 Interactions among the elements of a homeostatic control system maintain stable internal conditions.

narrow limits. In general, the body is in homeostasis when its needs are adequately met and it is functioning smoothly.

Maintaining homeostasis is more complicated than it appears at first glance. Virtually every organ system plays a role in maintaining the constancy of the internal environment. Adequate blood levels of vital nutrients must be continuously present, and heart activity and blood pressure must be constantly monitored and adjusted so that the blood is propelled to all body tissues. Also, wastes must not be allowed to accumulate, and body temperature must be precisely controlled. A wide variety of chemical, thermal, and neural factors act and interact in complex ways—sometimes helping and sometimes hindering the body as it works to maintain its “steady rudder.”

Homeostatic Control

Communication within the body is essential for homeostasis. Communication is accomplished chiefly by the nervous and endocrine systems, which use neural electrical impulses or blood-borne hormones, respectively, as information carriers. We cover the details of how these two great regulating systems operate in later chapters, but here we explain the basic characteristics of control systems that promote homeostasis.

Regardless of the factor or event being regulated—the **variable**—all homeostatic control mechanisms are processes involving at least three components that work together (Figure 1.4). The first component, the **receptor**, is some type of sensor that monitors the environment and responds to changes, called *stimuli*, by sending information (input) to the second component, the **control center**. Input flows from the receptor to the control center along the so-called *afferent pathway*.

The **control center** determines the *set point*, which is the level or range at which a variable is to be maintained. It also analyzes the input it receives and determines the appropriate response or course of action. Information (output) then flows from the control center to the third component, the **effector**, along the *efferent*

pathway. (To help you remember the difference between “afferent” and “efferent,” you might note that information traveling along the afferent pathway *approaches* the control center and efferent information *exits* from the control center.)

The **effector** provides the means for the control center’s response (output) to the stimulus. The results of the response then *feed back* to influence the effect of the stimulus, either reducing it (in negative feedback) so that the whole control process is shut off, or enhancing it (in positive feedback) so that the whole process continues at an even faster rate.

Negative Feedback Mechanisms

Most homeostatic control mechanisms are **negative feedback mechanisms**. In these systems, the output shuts off the original effect of the stimulus or reduces its intensity. These mechanisms cause the variable to change in a direction *opposite* to that of the initial change, returning it to its “ideal” value; thus the name “negative” feedback mechanisms.

Let’s start with an example of a nonbiological negative feedback system: a home heating system connected to a temperature-sensing thermostat. The thermostat houses both the receptor (thermometer) and the control center. If the thermostat is set at 20°C (68°F), the heating system (effector) is triggered ON when the house temperature drops below that setting. As the furnace produces heat and warms the air, the temperature rises, and when it reaches 20°C or slightly higher, the thermostat triggers the furnace OFF. This process results in a cycling of “furnace-ON” and “furnace-OFF” so that the temperature in the house stays very near the desired temperature of 20°C. Your body “thermostat,” located in a part of your brain called the hypothalamus, operates in a similar fashion (Figure 1.5).

Regulation of body temperature is only one of the many ways the nervous system maintains the constancy of the internal environment. Another type of neural control mechanism is seen in the *withdrawal reflex* mentioned earlier, in which the hand is jerked away from a painful stimulus such as broken glass.

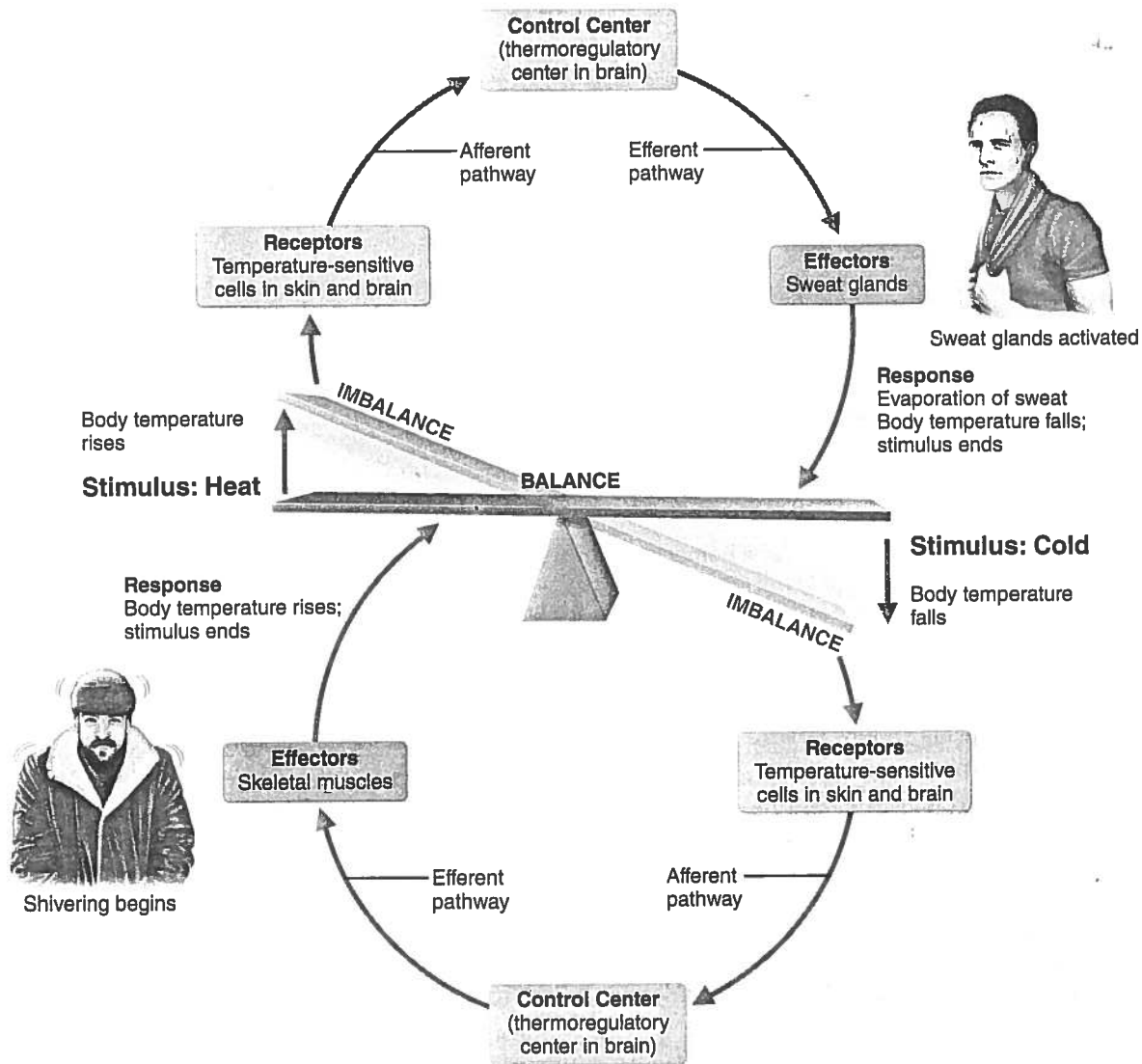


Figure 1.5 Body temperature is regulated by a negative feedback mechanism.

The endocrine system is equally important in maintaining homeostasis. A good example of a hormonal negative feedback mechanism is the control of blood sugar (glucose) by insulin. As blood sugar rises, receptors in the body sense this change, and the pancreas (the control center) secretes insulin into the blood. This change in turn prompts body cells to absorb more glucose, removing it from the bloodstream. As blood sugar falls, the stimulus for insulin release ends. The body's ability to regulate its internal environment is fundamental. All negative feedback mechanisms have the same goal: preventing sudden severe changes within the body. Body temperature and blood volume are only two of the variables that need to be regulated. There are hundreds! Other negative feedback mechanisms regulate heart rate, blood pressure, the rate and depth of breathing, and blood levels of oxygen, carbon dioxide, and minerals. Now, let's take a look at the other type of feedback control mechanism—positive feedback.

Positive Feedback Mechanisms

In **positive feedback mechanisms**, the result or response enhances the original stimulus so that the response is accelerated. This feedback mechanism is "positive" because the change that results proceeds in the *same* direction as the initial change, causing the variable to deviate further and further from its original value or range.

In contrast to negative feedback controls, which maintain some physiological function or keep blood chemicals within narrow ranges, positive feedback mechanisms usually control infrequent events that do not require continuous adjustments. Typically, they set off a series of events that may be self-perpetuating and that, once initiated, have an amplifying or waterfall effect. Because of these characteristics, positive feedback mechanisms are often referred to as *cascades* (from the Italian word meaning "to fall"). Two familiar examples of their use as homeostatic mechanisms are the enhancement of labor contractions during birth and blood clotting.



Chapter 28 describes the positive feedback mechanism in which oxytocin, a hypothalamic hormone, intensifies labor contractions during the birth of a baby (see Figure 28.17). Oxytocin causes the contractions to become both more frequent and more powerful. The increased contractions cause more oxytocin to be released, which causes more contractions, and so on until the baby is finally born. The birth ends the stimulus for oxytocin release and shuts off the positive feedback mechanism.

Blood clotting is a normal response to a break in the wall of a blood vessel and is an excellent example of an important body function controlled by positive feedback. Basically, once a vessel has been damaged, blood elements called platelets immediately begin to cling to the injured site and release chemicals that attract more platelets. This rapidly growing pileup of platelets temporarily “plugs” the tear and initiates the sequence of events that finally forms a clot (**Figure 1.6**). Positive feedback mechanisms are likely to race out of control, so they are rarely used to promote the moment-to-moment well-being of the body. However, some positive feedback mechanisms, including this one, may have only local reach. For example, blood clotting is accelerated in injured vessels, but does not normally spread to the entire circulation.

Homeostatic Imbalance

Homeostasis is so important that most disease can be regarded as a result of its disturbance, a condition called **homeostatic imbalance**. As we age, our body’s control systems become less efficient, and our internal environment becomes less and less stable. These events increase our risk for illness and produce the changes we associate with aging.

Another important source of homeostatic imbalance occurs when the usual negative feedback mechanisms are overwhelmed and destructive positive feedback mechanisms take over. Some instances of heart failure reflect this phenomenon.

Examples of homeostatic imbalance appear throughout this book to enhance your understanding of normal physiological mechanisms. This symbol  introduces the homeostatic imbalance sections and alerts you to the fact that we are describing an abnormal condition. Each Homeostatic Imbalance section is numbered to correspond with critical thinking questions available in the Study Area of MasteringA&P—visit www.masteringaandp.com to find Homeostatic Imbalance questions and other helpful study tools. 

✓ Check Your Understanding

9. What process allows us to adjust to either extreme heat or extreme cold?
10. When we begin to get dehydrated, we usually get thirsty, which causes us to drink fluids. Is thirst part of a negative or a positive feedback control system? Defend your choice.
11. Why is the control mechanism shown in Figure 1.6 called a positive feedback system? What event ends it?

For answers, see Appendix H.

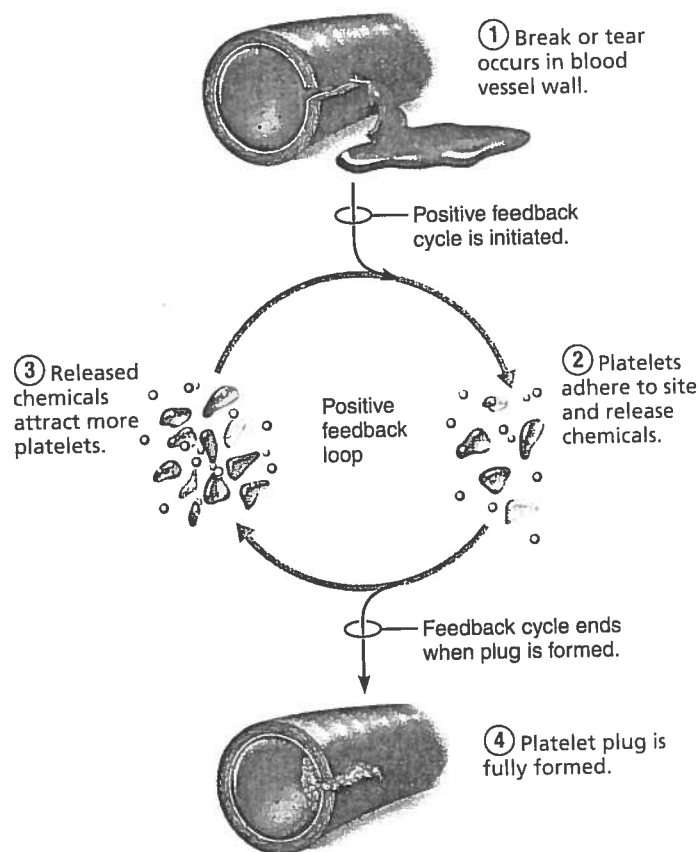


Figure 1.6 A positive feedback mechanism regulates formation of a platelet plug.

The Language of Anatomy

- ✓ Describe the anatomical position.
- ✓ Use correct anatomical terms to describe body directions, regions, and body planes or sections.






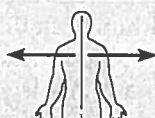





Most of us are naturally curious about our bodies, but our interest sometimes dwindles when we are confronted with the terminology of anatomy and physiology. Let’s face it—you can’t just pick up an anatomy and physiology book and read it as though it were a novel.

Unfortunately, confusion is likely without precise, specialized terminology. To prevent misunderstanding, anatomists use universally accepted terms to identify body structures precisely and with a minimum of words. We present and explain the language of anatomy next.

Anatomical Position and Directional Terms

To describe body parts and position accurately, we need an initial reference point, and we must indicate direction. The anatomical reference point is a standard body position called the **anatomical position**. In the anatomical position, the body is erect with feet slightly apart. This position is easy to remember because it resembles “standing at attention,” except that the palms face

Table 1.1 Orientation and Directional Terms

TERM	DEFINITION	EXAMPLE	
Superior (cranial)	Toward the head end or upper part of a structure or the body; above		The head is superior to the abdomen.
Inferior (caudal)	Away from the head end or toward the lower part of a structure or the body; below		The navel is inferior to the chin.
Ventral (anterior)*	Toward or at the front of the body; in front of		The breastbone is anterior to the spine.
Dorsal (posterior)*	Toward or at the back of the body; behind		The heart is posterior to the breastbone.
Medial	Toward or at the midline of the body; on the inner side of		The heart is medial to the arm.
Lateral	Away from the midline of the body; on the outer side of		The arms are lateral to the chest.
Intermediate	Between a more medial and a more lateral structure		The collarbone is intermediate between the breastbone and shoulder.
Proximal	Closer to the origin of the body part or the point of attachment of a limb to the body trunk		The elbow is proximal to the wrist.
Distal	Farther from the origin of a body part or the point of attachment of a limb to the body trunk		The knee is distal to the thigh.
Superficial (external)	Toward or at the body surface		The skin is superficial to the skeletal muscles.
Deep (internal)	Away from the body surface; more internal		The lungs are deep to the skin.

*The terms *ventral* and *anterior* are synonymous in humans, but this is not the case in four-legged animals. *Anterior* refers to the leading portion of the body (abdominal surface in humans, head in a cat), but *ventral* specifically refers to the "belly" of a vertebrate animal, so it is the inferior surface of four-legged animals. Likewise, although the dorsal and posterior surfaces are the same in humans, the term *dorsal* specifically refers to an animal's back. Thus, the dorsal surface of four-legged animals is their superior surface.

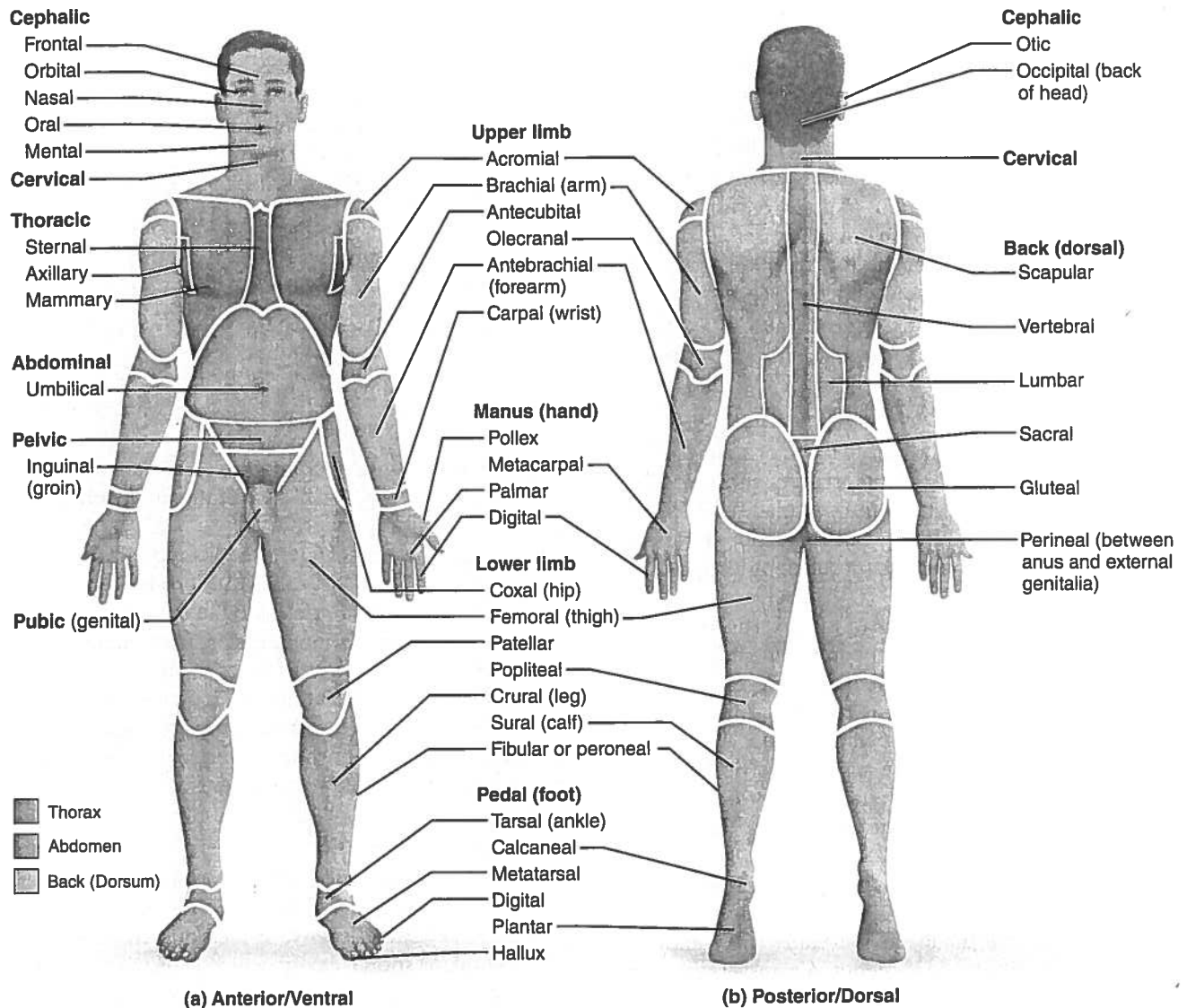


Figure 1.7 Regional terms used to designate specific body areas. (a) The anatomical position. **(b)** The heels are raised to show the plantar surface of the foot, which is actually on the inferior surface of the body.

forward and the thumbs point away from the body. You can see the anatomical position in **Table 1.1** (top) and **Figure 1.7a**.

It is essential to understand the anatomical position because most of the directional terms used in this book refer to the body *as if it were in this position, regardless of its actual position*. Another point to remember is that the terms “right” and “left” refer to those sides of the person or the cadaver (body of a deceased person) being viewed—not those of the observer.

Directional terms allow us to explain where one body structure is in relation to another. For example, we could describe the relationship between the ears and the nose informally by stating, “The ears are located on each side of the head to the right and left of the nose.” Using anatomical terminology, we can condense this to “The ears are lateral to the nose.” Using anatomical terms saves words and is less ambiguous.

Commonly used orientation and directional terms are defined and illustrated in **Table 1.1**. Many of these terms are also used in everyday conversation, but keep in mind as you study them that their anatomical meanings are very precise.

Regional Terms

The two fundamental divisions of our body are its *axial* and *appendicular* (ap'en-dik'u-lar) parts. The **axial part**, which makes up the main *axis* of our body, includes the head, neck, and trunk. The **appendicular part** consists of the *appendages*, or *limbs*, which are attached to the body's axis. **Regional terms** used to designate specific areas within these major body divisions are indicated in **Figure 1.7**. The common terms for a few of these body regions are given in parentheses.

Anatomical Variability

Although we use common directional and regional terms to refer to all human bodies, you know from observing the faces and body shapes of people around you that we humans differ in our external anatomy. The same kind of variability holds for internal organs as well. In some bodies, for example, a nerve or blood vessel may be somewhat out of place, or a small muscle may be missing. Nonetheless, well over 90% of all structures present in any human body match the textbook descriptions. We seldom see extreme anatomical variations because they are incompatible with life.

Body Planes and Sections

For anatomical studies, the body is often cut, or *sectioned*, along a flat surface called a *plane*. The most frequently used body planes are *sagittal*, *frontal*, and *transverse* planes, which lie at right angles to one another (**Figure 1.8**). A section is named for the plane along which it is cut. Thus, a cut along a sagittal plane produces a sagittal section.

A **sagittal plane** (saj'i-tal; "arrow") is a vertical plane that divides the body into right and left parts. A sagittal plane that lies exactly in the midline is the **median plane**, or **midsagittal plane** (Figure 1.8c). All other sagittal planes, offset from the midline, are **parasagittal planes** (*para* = near).

Frontal planes, like sagittal planes, lie vertically. Frontal planes, however, divide the body into anterior and posterior parts (Figure 1.8a). A frontal plane is also called a **coronal plane** (kō-ro'nal; "crown").

A **transverse**, or **horizontal**, **plane** runs horizontally from right to left, dividing the body into superior and inferior parts (Figure 1.8b). Of course, many different transverse planes exist, at every possible level from head to foot. A transverse section is also called a **cross section**.

Oblique sections are cuts made diagonally between the horizontal and the vertical planes. Because oblique sections are often confusing and difficult to interpret, they are seldom used.

At the bottom of Figure 1.8, you can see examples of magnetic resonance imaging (MRI) scans that correspond to the three different sections shown in the figure. Clinically, the ability to interpret sections made through the body, especially transverse sections, is important. Additionally, the new medical imaging devices (*A Closer Look*, pp. 16–17) produce sectional images rather than three-dimensional images.

It takes practice to determine or figure out an object's overall shape from sectioned material. A cross section of a banana, for example, looks like a circle and gives no indication of the whole banana's crescent shape. Likewise, sectioning the body or an organ along different planes often results in very different views. For example, a transverse section of the body trunk at the level of the kidneys would show kidney structure in cross section very nicely. A frontal section of the body trunk would show a different view of kidney anatomy, and a midsagittal section would miss the kidneys completely. With experience, you will gradually learn to relate two-dimensional sections to three-dimensional shapes.

✓ Check Your Understanding

- What is the anatomical position? Why is it important that you learn this position?
- The axillary and acromial regions are both in the general area of the shoulder. Where specifically is each located?
- What type of cut would separate the brain into anterior and posterior parts?

For answers, see Appendix H.

Body Cavities and Membranes

- ✓ Locate and name the major body cavities and their subdivisions and associated membranes, and list the major organs contained within them.
- ✓ Name the four quadrants or nine regions of the abdominopelvic cavity and list the organs they contain.

Anatomy and physiology textbooks typically describe two sets of internal body cavities called the dorsal and ventral body cavities. These cavities are closed to the outside and provide different degrees of protection to the organs contained within them. Because these two cavities differ in their mode of embryonic development, and their lining membranes, the dorsal body cavity is not recognized as such in many anatomical references. However, the idea of two sets of internal body cavities is a useful learning concept and we use it here.

Dorsal Body Cavity

The **dorsal body cavity**, which protects the fragile nervous system organs, has two subdivisions (**Figure 1.9**, on p. 18, gold areas). The **cranial cavity**, in the skull, encases the brain. The **vertebral**, or **spinal**, **cavity**, which runs within the bony vertebral column, encloses the delicate spinal cord. The spinal cord is essentially a continuation of the brain, and the cranial and spinal cavities are continuous with one another.

Ventral Body Cavity

The more anterior and larger of the closed body cavities is the **ventral body cavity** (Figure 1.9, deep-red areas). Like the dorsal cavity, it has two major subdivisions, the **thoracic cavity** and the **abdominopelvic cavity**. The ventral body cavity houses internal organs collectively called the **viscera** (vis'er-ah; *viscus* = an organ in a body cavity), or visceral organs.

The superior subdivision, the **thoracic cavity** (tho-ras'ik), is surrounded by the ribs and muscles of the chest. The thoracic cavity is further subdivided into lateral **pleural cavities** (plo'o'ral), each enveloping a lung, and the medial **mediastinum** (me'de-ah-sti'nūm). The mediastinum contains the **pericardial cavity** (per'i-kar'de-al), which encloses the heart, and it also surrounds the remaining thoracic organs (esophagus, trachea, and others).

The thoracic cavity is separated from the more inferior **abdominopelvic cavity** (ab-dom'i-no-pel'vic) by the diaphragm, a dome-shaped muscle important in breathing. The abdominopelvic cavity, as its name suggests, has two parts. However,

(Text continues on p. 18.)

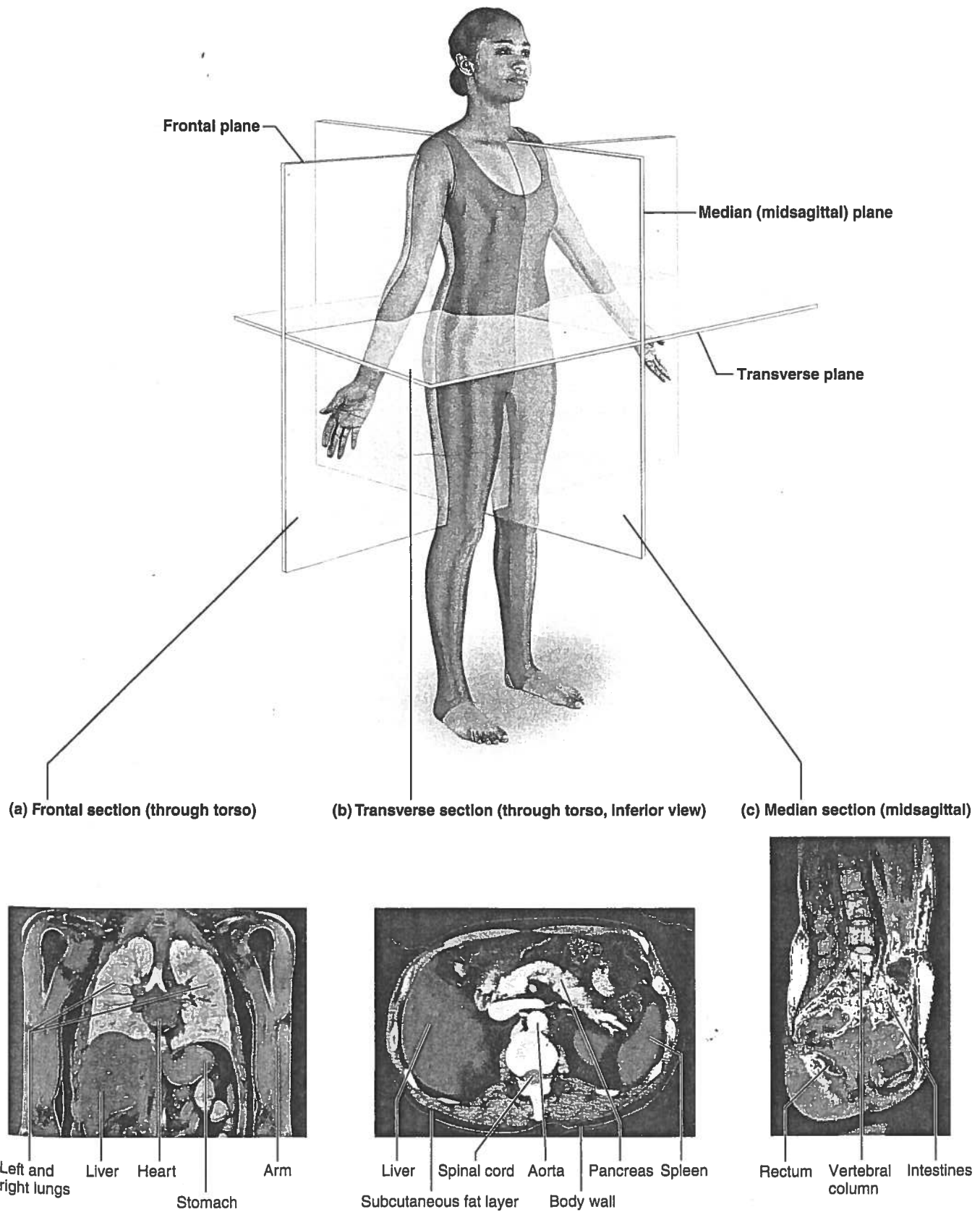


Figure 1.8 Planes of the body with corresponding magnetic resonance imaging (MRI) scans.

Medical Imaging: Illuminating the Body

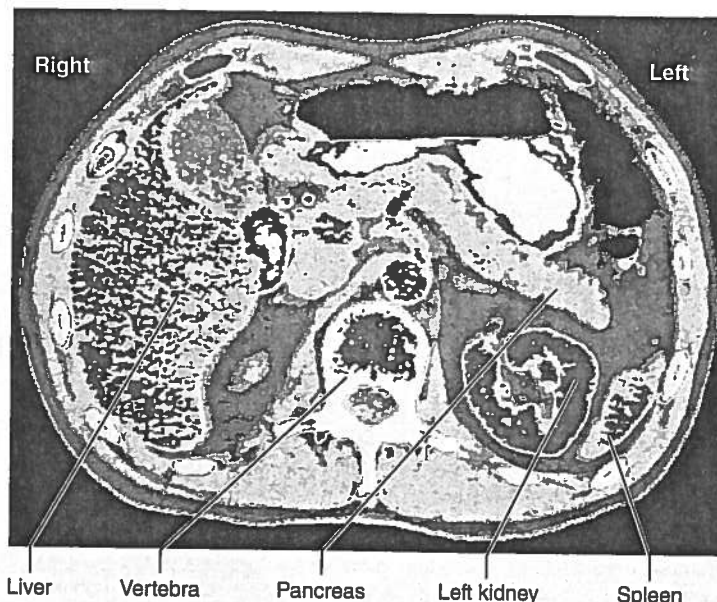
Until 50 years ago, the **magical** but **murky** X ray was the only nonsurgical means to extract information from within a living body. Produced by directing **X rays**, electromagnetic waves of very short wavelength, at the body, an **X ray** or **radiograph** is essentially a **shadowy negative image** of internal structures. Dense structures absorb the X rays most and so appear as light areas. Hollow air-containing organs and fat, which absorb the X rays less, show up as dark areas. What X rays do best is visualize hard, bony structures and locate abnormally dense structures (tumors, tuberculosis nodules) in the lungs.

The 1950s saw the advent of ultrasound and of nuclear medicine, which uses radioisotopes to scan the body to not only reveal the structure of our "insides" but also wring out information about the hidden workings of their molecules.

Computed tomography (CT), formerly called **computerized axial tomography, CAT** uses a refined version of X-ray equipment. As the patient is slowly moved through the doughnut-shaped CT machine, its X-ray tube rotates around the body and sends beams from all directions to a specific level of the patient's body. Because at any moment its beam is confined to a "slice" of the body about as thick as a dime, CT ends the confusion resulting from overlapping structures seen in conventional X rays. The device's computer translates this information into a detailed, cross-sectional picture of each body region scanned. CT scans are at the forefront for evaluating most problems that affect the brain and abdomen. Their clarity, illustrated in photo (a), has all but eliminated exploratory surgery.

Xenon CT is a CT brain scan enhanced with radioactive xenon gas to quickly trace blood flow. Inhaled xenon rapidly enters the bloodstream and distributes to different body tissues in proportion to their blood flow. Absence of xenon from part of the brain indicates that a stroke is occurring there, information that aids treatment.

Dynamic spatial reconstruction (DSR) uses ultrafast CT scanners to provide three-dimensional images of body organs from any angle, and scrutinize their movements and changes in their internal volumes at normal speed, in slow motion, and at a specific moment. DSR's greatest value has been to visualize the heart beating and blood flowing through blood vessels. This information



(a) A CT scan through the superior abdomen.

allows clinicians to evaluate heart defects, constricted or blocked blood vessels, and the status of coronary bypass grafts.

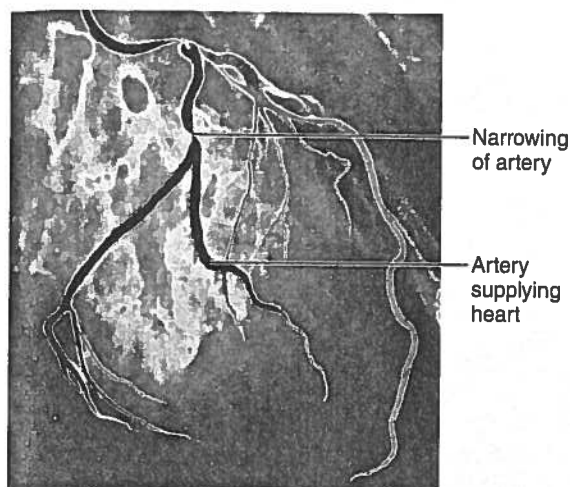
Another computer-assisted X-ray technique, **digital subtraction angiography (DSA)** (*angiography* = vessel pictures), provides an unobstructed view of small arteries. Conventional radiographs are taken before and after a contrast medium is injected into an artery. The computer subtracts the "before" image from the "after" image, eliminating all traces of body structures that obscure the vessel. DSA is often used to identify blockages in the arteries that supply the heart wall, as in photo (b), and in the brain.

Just as the X ray spawned related technologies, so too did nuclear medicine in the form of **positron emission tomography (PET)**. PET excels in observing *metabolic processes*. The patient is given an injection of radioisotopes tagged to biological molecules (such as glucose) and is then positioned in the PET scanner. As the radioisotopes are absorbed by the most active brain cells, high-energy gamma rays are produced. The computer analyzes the gamma-ray emission and produces a live-action picture of the brain's biochemical activity in vivid colors. PET's greatest value has been its ability to provide insights into brain activity in people affected by mental illness, stroke, Alzheimer's disease, and epilepsy. One of its most exciting uses has been to determine which areas of the healthy brain

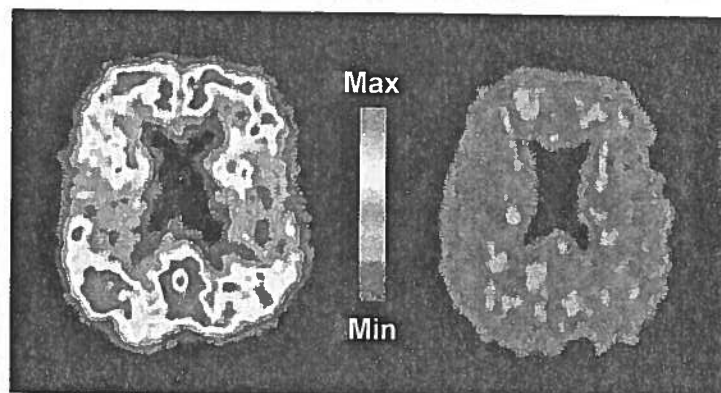
are most active during certain tasks (e.g., speaking, listening to music, or figuring out a mathematical problem), providing direct evidence of the functions of specific brain regions. Currently PET can reveal signs of trouble in those with undiagnosed Alzheimer's disease (AD) because regions of beta-amyloid accumulation (a defining characteristic of AD) show up in brilliant red and yellow, as in photo (c). PET scans can also help to predict who may develop AD in the future by identifying areas of decreased metabolism in crucial memory areas of the brain.

Sonography, or **ultrasound imaging**, has some distinct advantages over the approaches examined so far. The equipment is inexpensive, and the ultrasound used as its energy source seems to be safer than the ionizing forms of radiation used in nuclear medicine. The body is probed with pulses of sound waves that cause echoes when reflected and scattered by body tissues. A computer analyzes these echoes to construct somewhat blurry outlines of body organs. A single easy-to-use handheld device emits the sound and picks up the echoes, so sections can be scanned from many different body planes.

Because of its safety, ultrasound is the imaging technique of choice in obstetrics for determining fetal age and position and locating the placenta. However, sound waves have low penetrating power and rapidly dissipate in air, so sonography



(b) A DSA image of the arteries that supply the heart.



(c) In a PET scan, regions of beta-amyloid accumulation "light up" (red-yellow) in an Alzheimer's patient (left) but not in a healthy person (right).

is of little value for looking at air-filled structures (the lungs) or those surrounded by bone (the brain and spinal cord).

Magnetic resonance imaging (MRI) produces high-contrast images of our soft tissues, an area in which X rays and CT scans are weak. As initially developed, MRI primarily maps the body's content of hydrogen, most of which is in water. The technique subjects the body to magnetic fields up to 60,000 times stronger than that of the earth to pry information from the body's molecules. The patient lies in a chamber within a huge magnet. Hydrogen molecules act like tiny magnets, spinning like tops in the magnetic field. Their energy is further enhanced by radio waves, and when the radio waves are turned off, the energy released is translated into a visual image.

MRI distinguishes body tissues based on their water content, so it can differentiate between the fatty white matter and the more watery gray matter of the brain. Because dense structures do not show up at all in MRI, it peers easily into the skull and vertebral column, enabling the delicate nerve fibers of the spinal cord to be seen. MRI is also particularly good at detecting tumors and degenerative disease. Multiple sclerosis plaques do not show up well in CT scans, but are dazzlingly clear in MRI scans. MRI can also tune in on metabolic reactions, such as processes that generate energy-rich ATP molecules.

Until recently, trying to diagnose asthma and other lung problems has been off limits to MRI scans because the lungs have a low water content. However, an alternate tack—filling the lungs with a gas that can be magnetized (hyperpolarized helium-3 or xenon-129)—has yielded spectacular pictures

of the lungs in just the few seconds it takes the patient to inhale, hold the breath briefly, and then exhale. This technique offers a distinct improvement over the hours required for conventional MRI and it has the additional advantage of using a magnetic field as little as one-tenth that of the conventional MRI. Lately, MRI scans have become the "diagnostic darling" in emergency rooms for their ability to accurately diagnose heart attacks or ischemic strokes—conditions that require rapid treatment to prevent fatal consequences. Also exciting are the so-called **bloodless MRIs** currently being tested in animals, which measure water flow instead of blood flow.

Newer variations of MRI include **magnetic resonance spectroscopy (MRS)**, which maps the distribution of elements other than hydrogen to reveal more about how disease changes body chemistry. Other advances in computer techniques display MRI scans in three dimensions to guide laser surgery.

The **functional MRI** tracks blood flow into the brain in real time. Prior to the 1990s, matching thoughts, deeds, and disease to brain activity was the sole domain of PET. Because functional MRI does not require injections of tracers and can pinpoint much smaller brain areas than PET, it may provide a desirable alternative and has transformed neuroscience. Clinical studies are also using functional MRI to determine if a patient in the vegetative state has conscious thought. However, some researchers worry that the brightly colored images explain little about the mechanisms of human thought—that is, it is not possible to assume a particular mental state from the activation of a particular brain region.

Despite its advantages, the powerful magnets of the clanging, claustrophobia-inducing MRI present some thorny problems. For example, they can "suck" metal objects, such as implanted pacemakers and loose tooth fillings, through the body. Moreover, although such strong magnetic fields are currently considered safe, there is no convincing evidence that they are risk free.

Although stunning, medical images other than straight X rays are abstractions assembled within the "mind" of a computer. They are artificially enhanced for sharpness and artificially colored to increase contrast (all their colors are "phony"). The images are several steps removed from direct observation.

As you can see, medical science offers remarkable diagnostic tools. Consider the **M2A Swallowable Imaging Capsule**, a tiny camera that a patient swallows like a pill, and then excretes normally 8–72 hours later. As the M2A travels through the digestive tract, it photographs the small intestine and beams the color images to a small video data recorder worn on a belt or harness. A study found the device to be 60% effective at detecting intestinal problems, compared to a 35% success rate with other imaging techniques. At present the M2A can provide images only of the small intestine because the battery gives out before it enters the large intestine.

New imaging technologies also make long-distance surgery possible. Visual images of a diseased organ travel via fiber-optic cable to surgeons at another location (even a different country), who manipulate delicate robotic instruments to remove the organ.

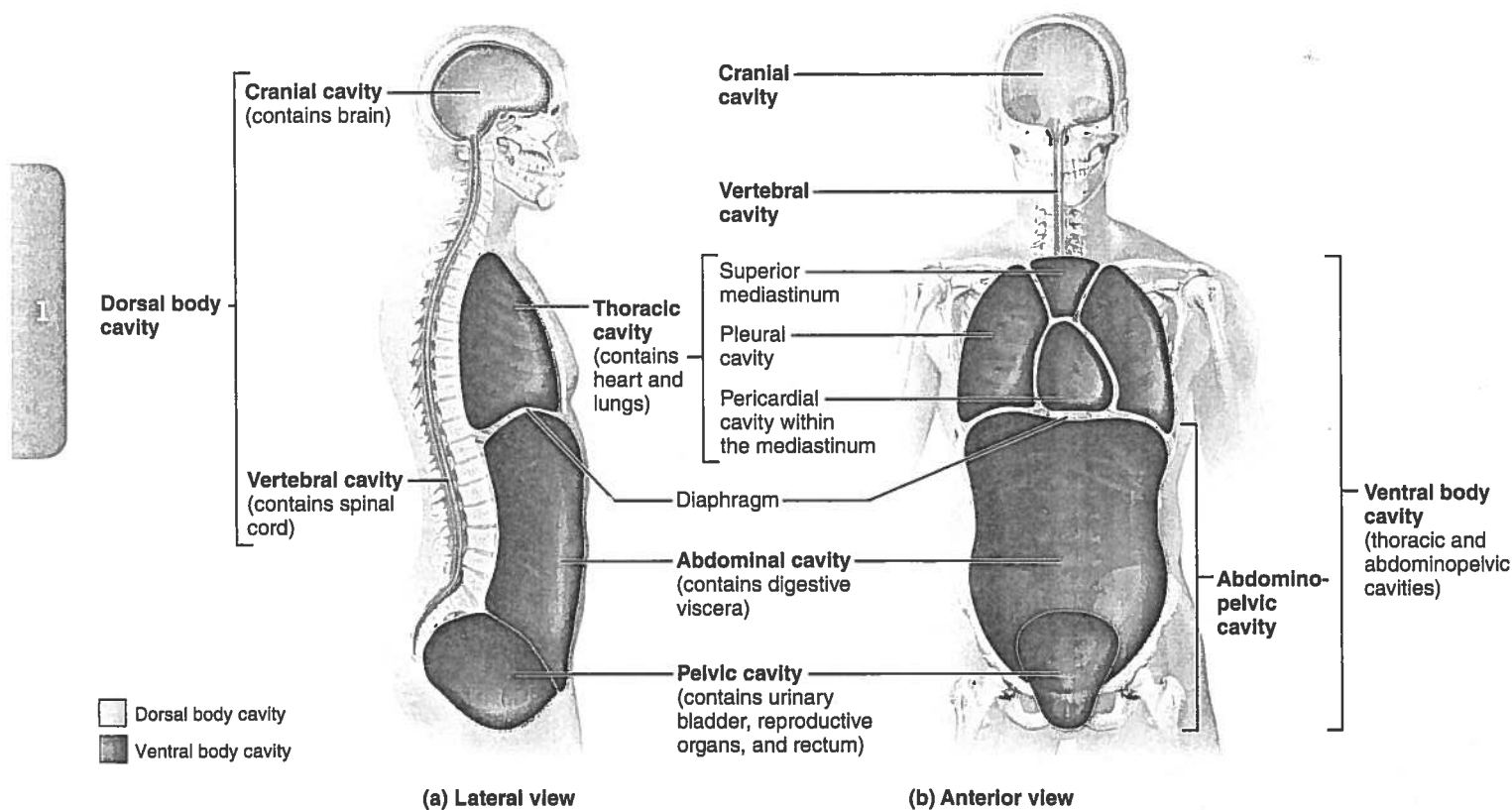


Figure 1.9 Dorsal and ventral body cavities and their subdivisions.

these regions are not physically separated by a muscular or membrane wall. Its superior portion, the **abdominal cavity**, contains the stomach, intestines, spleen, liver, and other organs. The inferior part, the **pelvic cavity**, lies in the bony pelvis and contains the urinary bladder, some reproductive organs, and the rectum. The abdominal and pelvic cavities are not aligned with each other. Instead, the bowl-shaped pelvis tips away from the perpendicular as shown in Figure 1.9a.



Homeostatic Imbalance 1.1

When the body is subjected to physical trauma (as in an automobile accident), the abdominopelvic organs are most vulnerable. Why? This is because the walls of the abdominal cavity are formed only by trunk muscles and are not reinforced by bone. The pelvic organs receive a somewhat greater degree of protection from the bony pelvis. ✚

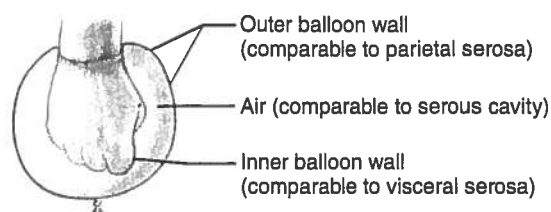
Membranes in the Ventral Body Cavity The walls of the ventral body cavity and the outer surfaces of the organs it contains are covered by a thin, double-layered membrane, the **serosa** (se-ro'sah), or **serous membrane**. The part of the membrane lining the cavity walls is called the **parietal serosa** (pah-ri'ě-tal; *parie* = wall). It folds in on itself to form the **visceral serosa**, covering the organs in the cavity.

You can visualize the relationship between the serosal layers by pushing your fist into a limp balloon (**Figure 1.10a**). The

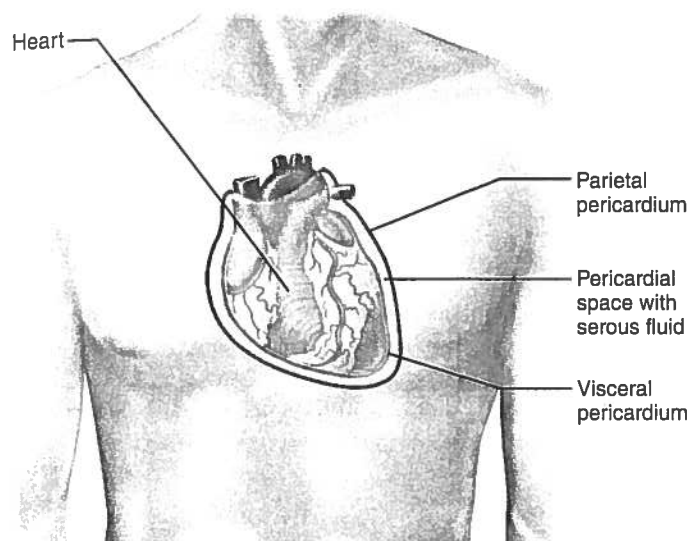
part of the balloon that clings to your fist can be compared to the visceral serosa clinging to an organ's external surface. The outer wall of the balloon then represents the parietal serosa that lines the walls of the cavity. (However, unlike the balloon, the parietal serosa is never exposed but is always fused to the cavity wall.) In the body, the serous membranes are separated not by air but by a thin layer of lubricating fluid, called **serous fluid**, which is secreted by both membranes. Although there is a potential space between the two membranes, the barely present, slitlike cavity is filled with serous fluid.

The slippery serous fluid allows the organs to slide without friction across the cavity walls and one another as they carry out their routine functions. This freedom of movement is especially important for mobile organs such as the pumping heart and the churning stomach.

The serous membranes are named for the specific cavity and organs with which they are associated. For example, as shown in Figure 1.10b, the *parietal pericardium* lines the pericardial cavity and folds back as the *visceral pericardium*, which covers the heart. Likewise, the *parietal pleurae* (plo'o're) line the walls of the thoracic cavity, and the *visceral pleurae* cover the lungs. The *parietal peritoneum* (per'i-to-ne'um) is associated with the walls of the abdominopelvic cavity, while the *visceral peritoneum* covers most of the organs within that cavity. (The pleural and peritoneal serosae are illustrated in Figure 4.11c on p. 141.)



(a) A fist thrust into a flaccid balloon demonstrates the relationship between the parietal and visceral serous membrane layers.



(b) The serosae associated with the heart.

Figure 1.10 Serous membrane relationships.

Homeostatic Imbalance 1.2

When serous membranes are inflamed, their normally smooth surfaces become roughened. This roughness causes the organs to stick together and drag across one another, leading to excruciating pain, as anyone who has experienced *pleurisy* (inflammation of the pleurae) or *peritonitis* (inflammation of the peritoneums) knows. +

Abdominopelvic Regions and Quadrants Because the abdominopelvic cavity is large and contains several organs, it helps to divide it into smaller areas for study. Medical personnel usually use a simple scheme to locate the abdominopelvic cavity organs (**Figure 1.11**). In this scheme, a transverse and a median plane pass through the umbilicus at right angles. The four resulting quadrants are named according to their positions from the subject's point of view: the **right upper quadrant (RUQ)**, **left upper quadrant (LUQ)**, **right lower quadrant (RLQ)**, and **left lower quadrant (LLQ)**.

Another division method, used primarily by anatomists, uses two transverse and two parasagittal planes. These planes, positioned like a tic-tac-toe grid on the abdomen, divide the cavity into nine regions (**Figure 1.12**):

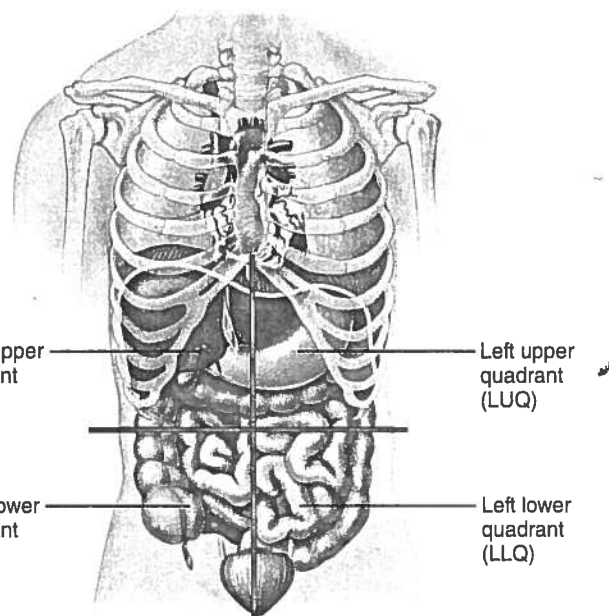


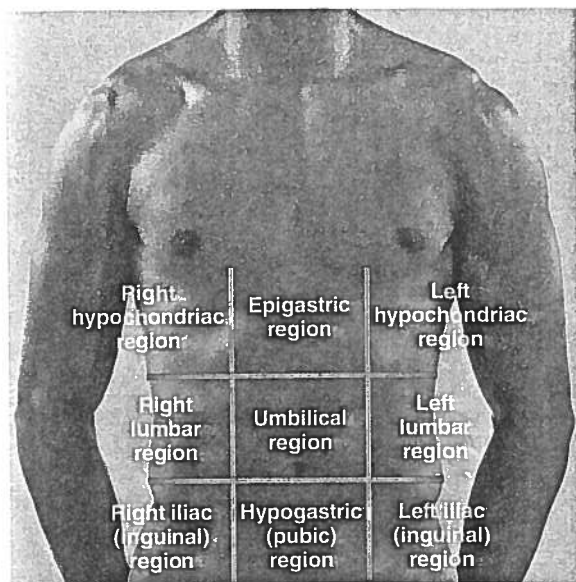
Figure 1.11 The four abdominopelvic quadrants. In this scheme, the abdominopelvic cavity is divided into four quadrants by two planes.

- The **umbilical region** is the centermost region deep to and surrounding the umbilicus (navel).
- The **epigastric region** is located superior to the umbilical region (*epi* = upon, above; *gastri* = belly).
- The **hypogastric (pubic) region** is located inferior to the umbilical region (*hypo* = below).
- The **right and left iliac, or inguinal, regions** (ing'gwī-nal) are located lateral to the hypogastric region (*iliac* = superior part of the hip bone).
- The **right and left lumbar regions** lie lateral to the umbilical region (*lumbus* = loin).
- The **right and left hypochondriac regions** lie lateral to the epigastric region and deep to the ribs (*chondro* = cartilage).

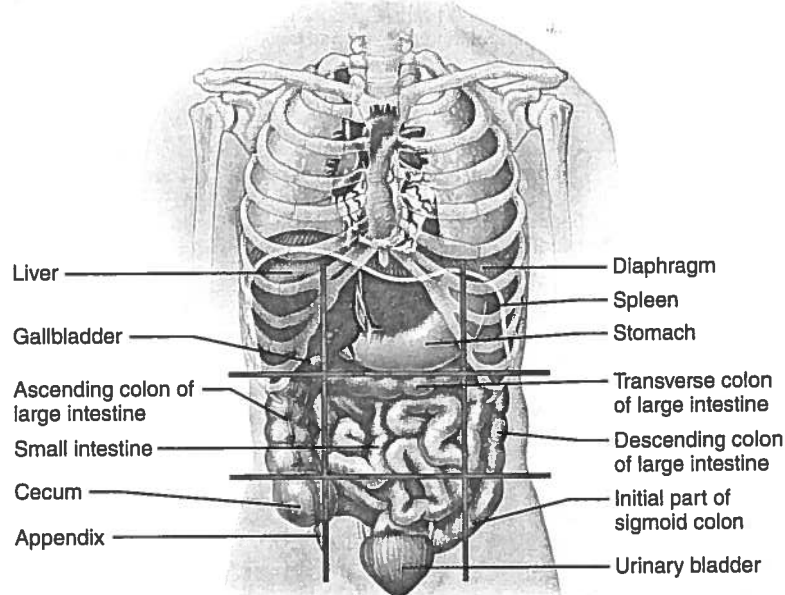
Other Body Cavities

In addition to the large closed body cavities, there are several smaller body cavities. Most of these are in the head and most open to the body exterior. Figure 1.7 provides the terms that will help you locate all but the last two cavities mentioned here.

- **Oral and digestive cavities.** The oral cavity, commonly called the mouth, contains the teeth and tongue. This cavity is part of and continuous with the cavity of the digestive organs, which opens to the body exterior at the anus.
- **Nasal cavity.** Located within and posterior to the nose, the nasal cavity is part of the respiratory system passageways.
- **Orbital cavities.** The orbital cavities (orbits) in the skull house the eyes and present them in an anterior position.



(a) Nine regions delineated by four planes



(b) Anterior view of the nine regions showing the superficial organs

Figure 1.12 The nine abdominopelvic regions. In (a) the superior transverse plane is just inferior to the ribs; the inferior transverse plane is just superior to the hip bones; and the parasagittal planes lie just medial to the nipples.

- **Middle ear cavities.** The middle ear cavities in the skull lie just medial to the eardrums. These cavities contain tiny bones that transmit sound vibrations to the hearing receptors in the inner ears.
- **Synovial cavities.** Synovial (sī-no've-al) cavities are joint cavities. They are enclosed within fibrous capsules that surround freely movable joints of the body (such as the elbow and knee joints). Like the serous membranes, membranes lining synovial cavities secrete a lubricating fluid that reduces friction as the bones move across one another.

✓ Check Your Understanding

15. Joe went to the emergency room where he complained of severe pains in the lower right quadrant of his abdomen. What might be his problem?
16. Of the uterus, small intestine, spinal cord, and heart, which is/are in the dorsal body cavity?
17. When you rub your cold hands together, the friction between them results in heat that warms your hands. Why doesn't warming friction result during movements of the heart, lungs, and digestive organs?

For answers, see Appendix H.

Chapter Summary



For more chapter study tools, go to the Study Area of MasteringA&P.

There you will find:

- Interactive Physiology **iP**
- A&PFlix **A&PFlix**
- Practice Anatomy Lab **PAL**
- PhysioEx **PEX**
- Videos, Practice Quizzes and Tests, MP3 Tutor Sessions, Case Studies, and much more!

An Overview of Anatomy and Physiology (pp. 2–3)

1. Anatomy is the study of body structures and their relationships. Physiology is the science of how body parts function.

Topics of Anatomy (p. 2)

2. Major subdivisions of anatomy include gross anatomy, microscopic anatomy, and developmental anatomy.

Topics of Physiology (pp. 2–3)

3. Typically, physiology concerns the functioning of specific organs or organ systems. Examples include cardiac physiology, renal physiology, and muscle physiology.
4. Physiology is explained by chemical and physical principles.

Complementarity of Structure and Function (p. 3)

5. Anatomy and physiology are inseparable: What a body can do depends on the unique architecture of its parts. This principle is called the complementarity of structure and function.

Levels of Structural Organization (pp. 3–4)

1. The levels of structural organization of the body, from simplest to most complex, are: chemical, cellular, tissue, organ, organ system, and organismal.
2. The 11 organ systems of the body are the integumentary, skeletal, muscular, nervous, endocrine, cardiovascular, lymphatic, respiratory, digestive, urinary, and reproductive systems. The immune system is a functional system closely associated with the lymphatic system. (For functions of these systems see pp. 6–7.)

Maintaining Life (pp. 4–8)**Necessary Life Functions (pp. 4–8)**

1. All living organisms carry out certain vital functional activities necessary for life, including maintenance of boundaries, movement, responsiveness, digestion, metabolism, excretion, reproduction, and growth.

Survival Needs (p. 8)

2. Survival needs include nutrients, water, oxygen, and appropriate temperature and atmospheric pressure.

Homeostasis (pp. 8–11)

1. Homeostasis is a dynamic equilibrium of the internal environment. All body systems contribute to homeostasis, but the nervous and endocrine systems are most important. Homeostasis is necessary for health.

Homeostatic Control (pp. 9–11)

2. Control mechanisms of the body contain at least three elements that work together: receptor(s), control center, and effector(s).
3. Negative feedback mechanisms reduce the effect of the original stimulus, and are essential for maintaining homeostasis. Body temperature, heart rate, breathing rate and depth, and blood levels of glucose and certain ions are regulated by negative feedback mechanisms.
4. Positive feedback mechanisms intensify the initial stimulus, leading to an enhancement of the response. They rarely contribute to homeostasis, but blood clotting and labor contractions are regulated by such mechanisms.

Homeostatic Imbalance (p. 11)

5. With age, the efficiency of negative feedback mechanisms declines, and positive feedback mechanisms occur more frequently. These changes underlie certain disease conditions.

Review Questions**Multiple Choice/Matching**

(Some questions have more than one correct answer. Select the best answer or answers from the choices given.)

1. The correct sequence of levels forming the structural hierarchy is
(a) organ, organ system, cellular, chemical, tissue, organismal;
(b) chemical, cellular, tissue, organismal, organ, organ system;
(c) chemical, cellular, tissue, organ, organ system, organismal;
(d) organismal, organ system, organ, tissue, cellular, chemical.
2. The structural and functional unit of life is (a) a cell, (b) an organ, (c) the organism, (d) a molecule.

The Language of Anatomy (pp. 11–20)**Anatomical Position and Directional Terms (pp. 11–13)**

1. In the anatomical position, the body is erect, facing forward, feet slightly apart, arms at sides with palms forward.
2. Directional terms allow body parts to be located precisely. Terms that describe body directions and orientation include: superior/inferior; anterior/posterior; ventral/dorsal; medial/lateral; intermediate; proximal/distal; and superficial/deep.

Regional Terms (p. 13)

3. Regional terms are used to designate specific areas of the body (see Figure 1.7).

Anatomical Variability (p. 14)

4. People vary internally as well as externally, but extreme variations are rare.

Body Planes and Sections (p. 14)

5. The body or its organs may be cut along planes, or imaginary lines, to produce different types of sections. Frequently used planes are sagittal, frontal, and transverse.

Body Cavities and Membranes (pp. 14–20)

6. The body contains two major closed cavities. The dorsal cavity, subdivided into the cranial and spinal cavities, contains the brain and spinal cord. The ventral cavity is subdivided into the thoracic cavity, which houses the heart and lungs, and the abdominopelvic cavity, which contains the liver, digestive organs, and reproductive structures.
7. The walls of the ventral cavity and the surfaces of the organs it contains are covered with thin membranes, the parietal and visceral serosae, respectively. The serosae produce a thin fluid that decreases friction during organ functioning.
8. The abdominopelvic cavity may be divided by four planes into nine abdominopelvic regions (epigastric, umbilical, hypogastric, right and left iliac, right and left lumbar, and right and left hypochondriac), or by two planes into four quadrants. (For boundaries and organs contained, see Figures 1.11 and 1.12.)
9. There are several smaller body cavities. Most of these are in the head and open to the exterior.

3. Which of the following is a *major* functional characteristic of all organisms? (a) movement, (b) growth, (c) metabolism, (d) responsiveness, (e) all of these.
4. Two of these organ systems bear the *major* responsibility for ensuring homeostasis of the internal environment. Which two? (a) nervous system, (b) digestive system, (c) cardiovascular system, (d) endocrine system, (e) reproductive system.
5. In (a)–(e), a directional term [e.g., distal in (a)] is followed by terms indicating different body structures or locations (e.g., the

The Human Body: An Orientation



Student Objectives

When you have completed the exercises in this chapter, you will have accomplished the following objectives:

1.1 Form (anatomy) determines function (physiology)

- ☐ Define anatomy and physiology and describe their subdivisions.
- ☐ Explain the principle of complementarity.

1.2 The body's organization ranges from atoms to the entire organism

- ☐ Name the different levels of structural organization that make up the human body, and explain their relationships.
- ☐ List the 11 organ systems of the body, identify their components, and briefly explain the major function(s) of each system.

1.3 What are the requirements for life?

- ☐ List the functional characteristics necessary to maintain life in humans.
- ☐ List the survival needs of the body.

1.4 Homeostasis is maintained by negative feedback

- ☐ Define homeostasis and explain its significance.
- ☐ Describe how negative and positive feedback maintain body homeostasis.
- ☐ Describe the relationship between homeostatic imbalance and disease.

1.5 Anatomical terms describe body directions, regions, and planes

- ☐ Describe the anatomical position.
- ☐ Use correct anatomical terms to describe body directions, regions, and body planes or sections.

1.6 Many internal organs lie in membrane-lined body cavities

- ☐ Locate and name the major body cavities and their subdivisions and associated membranes, and list the major organs contained within them.
- ☐ Name the four quadrants or nine regions of the abdominopelvic cavity and list the organs they contain.

4. Using the key choices, identify the body systems to which the following organs or functions belong. Insert the correct answers in the answer blanks.

Key Choices

- | | | | |
|-------------------|-------------------------|-----------------|----------------|
| A. Cardiovascular | D. Integumentary | F. Muscular | I. Respiratory |
| B. Digestive | E. Lymphatic/
Immune | G. Nervous | J. Skeletal |
| C. Endocrine | | H. Reproductive | K. Urinary |

- | | |
|-------|---|
| _____ | 1. Rids the body of nitrogen-containing wastes |
| _____ | 2. Is affected by the removal of the thyroid gland |
| _____ | 3. Provides support and levers on which the muscular system can act |
| _____ | 4. Includes the heart |
| _____ | 5. Protects underlying organs from drying out and mechanical damage |
| _____ | 6. Protects the body; destroys bacteria and tumor cells |
| _____ | 7. Breaks down foodstuffs into small particles that can be absorbed |
| _____ | 8. Removes carbon dioxide from the blood |
| _____ | 9. Delivers oxygen and nutrients to the body tissues |
| _____ | 10. Moves the limbs; allows facial expression |
| _____ | 11. Conserves body water or eliminates excesses |
| _____ | 12. Allows conception and childbearing |
| _____ | 13. Controls the body with chemicals called hormones |
| _____ | 14. Is damaged when you cut your finger or get a severe sunburn |

5. Using the key choices from Exercise 4, choose the organ system to which each of the following sets of organs belongs. Enter the correct letters in the answer blanks.

- | | |
|--|--|
| _____ 1. Blood vessels, heart | _____ 5. Esophagus, large intestine, stomach |
| _____ 2. Pancreas, pituitary, adrenal glands | _____ 6. Breastbone, vertebral column, skull |
| _____ 3. Kidneys, bladder, ureters | _____ 7. Brain, nerves, sensory receptors |
| _____ 4. Testis, vas deferens, urethra | |

1.3 What are the requirements for life?

1. Match the terms pertaining to functional characteristics of organisms in Column B with the appropriate descriptions in Column A. Fill in the blanks with the appropriate answers.

Column A	Column B
_____ 1. Keeps the body's internal environment distinct from the external environment	A. Digestion
_____ 2. Provides new cells for growth and repair	B. Excretion
_____ 3. Occurs when constructive activities occur at a faster rate than destructive activities	C. Growth
_____ 4. The tuna sandwich you have just eaten is broken down into its chemical building blocks	D. Maintenance of boundaries
_____ 5. Elimination of carbon dioxide by the lungs and of nitrogenous wastes by the kidneys	E. Metabolism
_____ 6. Ability to react to stimuli; a major role of the nervous system	F. Movement
_____ 7. Walking, throwing a ball, riding a bicycle	G. Responsiveness
_____ 8. All chemical reactions occurring in the body	H. Reproduction
_____ 9. At the cellular level, membranes; for the whole organism, the skin	

2. Using the key choices, correctly identify the survival needs that correspond to the following descriptions. Insert the correct answers in the answer blanks.

Key Choices

- | | | |
|---------------------------------|--------------|----------|
| A. Appropriate body temperature | C. Nutrients | E. Water |
| B. Atmospheric pressure | D. Oxygen | |

- | |
|--|
| _____ 1. Includes carbohydrates, proteins, fats, and minerals |
| _____ 2. Essential for normal operation of the respiratory system and breathing |
| _____ 3. Single substance accounting for over 60% of body weight |
| _____ 4. Required for the release of energy from foodstuffs |
| _____ 5. Provides the basis for body fluids of all types |
| _____ 6. When too high or too low, physiological activities cease, primarily because molecules are destroyed or become nonfunctional |

1.5 Anatomical terms describe body directions, regions, and planes

1. Complete the following statements by choosing an anatomical term from the key choices. Enter the appropriate answers in the answer blanks.

Key Choices

- | | | | |
|-------------|-------------|--------------|---------------|
| A. Anterior | D. Inferior | G. Posterior | J. Superior |
| B. Distal | E. Lateral | H. Proximal | K. Transverse |
| C. Frontal | F. Medial | I. Sagittal | |

- _____ 1. In the anatomical position, the nose and belly button are on the _____ (1) body surface, the calves and shoulder blades are on the _____ (2) body surface, and the soles of the feet are the most _____ (3) part of the body. The nipples are _____ (4) to the shoulders and _____ (5) to the upper arms. The heart is _____ (6) to the spine and _____ (7) to the lungs. The knee is _____ (8) to the toes but _____ (9) to the thigh. In humans, the ventral surface can also be called the _____ (10) surface; however, in four-legged animals, the ventral surface is the _____ (11) surface.
- _____ 6. If an incision cuts the brain into right and left parts, the section is a(n) _____ (12) section, but if the brain is cut so that superior and inferior parts result, the section is a(n) _____ (13) section. You are told to cut an animal along two planes so that the paired lungs are observable in both sections. The two sections that meet this requirement are the _____ (14) and _____ (15) sections.
- _____ 9. The thoracic cavity is _____ (16) to the abdominopelvic cavity and _____ (17) to the spinal cavity.
- _____ 10. _____ 15.
- _____ 11. _____ 16.
- _____ 12. _____ 17.

2. In 1–6 below, a directional term (e.g., distal in 1) is followed by terms indicating different body structures or locations (e.g., the elbow/the shoulder). In each case, choose the structure or location that best matches the directional term given.

- | | |
|--|---|
| 1. Distal—the elbow/the shoulder | 4. Superficial—the skeleton/the muscles |
| 2. Lateral—the shoulder/the breastbone | 5. Proximal—the knee/the foot |
| 3. Superior—the forehead/the chin | 6. Inferior—the liver/the small intestine |

3. Circle the term or phrase that does *not* belong in each of the following groupings.

1. Transverse Distal Frontal Sagittal
2. Lumbar Antecubital Abdominal Scapular
3. Calf Brachial Femoral Popliteal
4. Epigastric Hypogastric Lumbar Left upper quadrant
5. Orbital cavity Nasal cavity Ventral cavity Oral cavity

4. Select the key choices (A–P) that identify the following body parts or areas (1–10). Enter the appropriate answers in the blanks.

Key Choices

Abdominal	Calf	Gluteal	Popliteal
Axillary	Cervical	Inguinal	Pubic
Brachial	Digital	Lumbar	Scapular
Buccal	Femoral	Occipital	Umbilical

- _____ 1. Armpit
- _____ 2. Thigh region
- _____ 3. Buttock area
- _____ 4. Neck region
- _____ 5. Belly button area
- _____ 6. Pertaining to the toes
- _____ 7. Posterior aspect of head
- _____ 8. Area where trunk meets thigh
- _____ 9. Back area from ribs to hips
- _____ 10. Pertaining to the cheek

5. Correctly label all body areas indicated with leader lines on Figure 1.7. Some of the terms you will need are in the key of Exercise 4; others will have to be provided from memory. In addition, identify the sections labeled A and B in the figure.

Section A: _____ Section B: _____

The body positions indicated by the diagrams in Figure 1.7 are fairly close to the anatomical position. What body part(s) are incorrectly depicted? How should they be depicted for anatomical position? _____

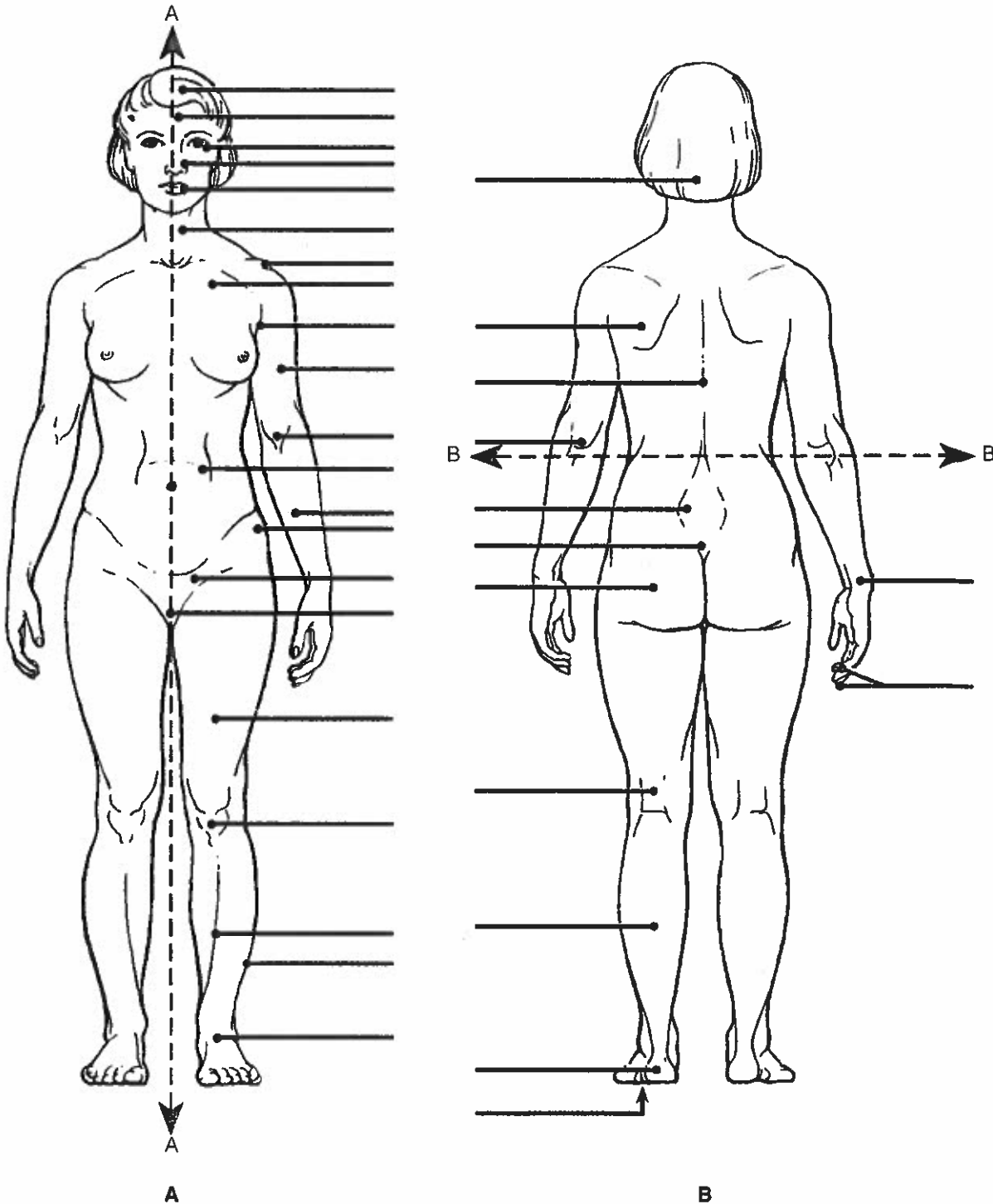


Figure 1.7

1.6 Many internal organs lie in membrane-lined body cavities

1. Complete the following statements by filling in the answer blanks with the correct terms.

- _____ 1. The abdominopelvic and thoracic cavities are subdivisions of the (1) body cavity; the cranial and spinal cavities are parts of the (2) body cavity. The (3) body cavity is totally surrounded by bone and provides very good protection to the structures it contains.

2. Identify the following serous membranes. Insert your answers in the answer blanks.

1. Covers the lungs and cavity of the thorax _____
2. Forms a slippery sac around the heart _____
3. Surrounds the abdominopelvic cavity organs _____

3. Using the key choices, identify the body cavities where the following body organs are located. Enter the appropriate answers in the answer blanks.

Key Choices

A. Abdominopelvic

B. Cranial

C. Spinal

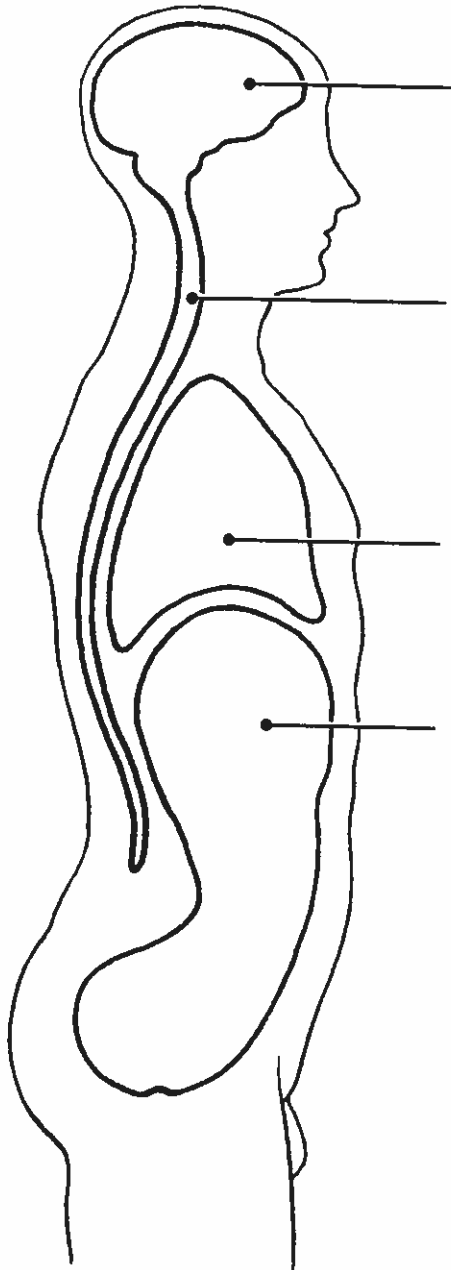
D. Thoracic

- | | |
|--------------------------|-------------------|
| _____ 1. Stomach | _____ 7. Bladder |
| _____ 2. Small intestine | _____ 8. Heart |
| _____ 3. Large intestine | _____ 9. Lungs |
| _____ 4. Spleen | _____ 10. Brain |
| _____ 5. Liver | _____ 11. Rectum |
| _____ 6. Spinal cord | _____ 12. Ovaries |

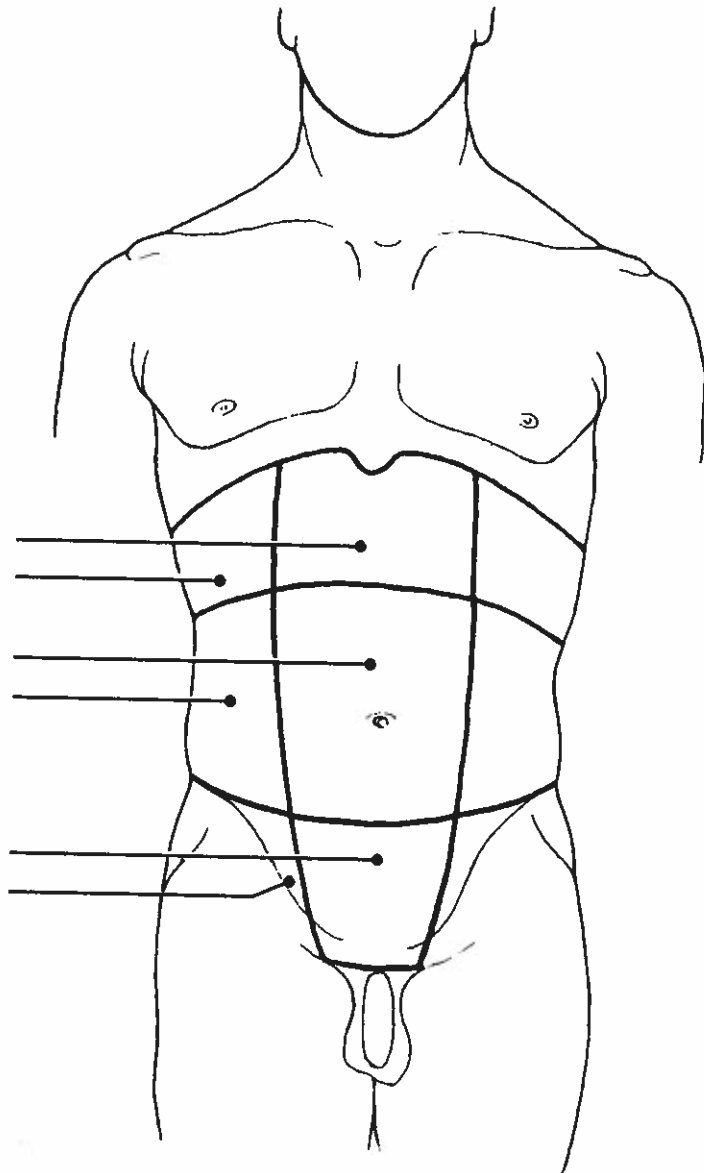
5. Select different colors for the dorsal and ventral body cavities. Color the coding circles below and the corresponding cavities in part A of Figure 1.8. Complete the figure by labeling those body cavity subdivisions that have a leader line. Complete part B by labeling each of the abdominal regions indicated by a leader line.

☐ Dorsal body cavity

☐ Ventral body cavity



A



B

Figure 1.8

6. Choose different colors for the cavities listed with color-coding circles. Color the coding circles and the corresponding cavities in Figure 1.9. Complete this exercise by identifying the structure provided with a leader line.

- ☐ Pleural cavities
- ☐ Pericardial cavity
- ☐ Abdominal cavity
- ☐ Pelvic cavity

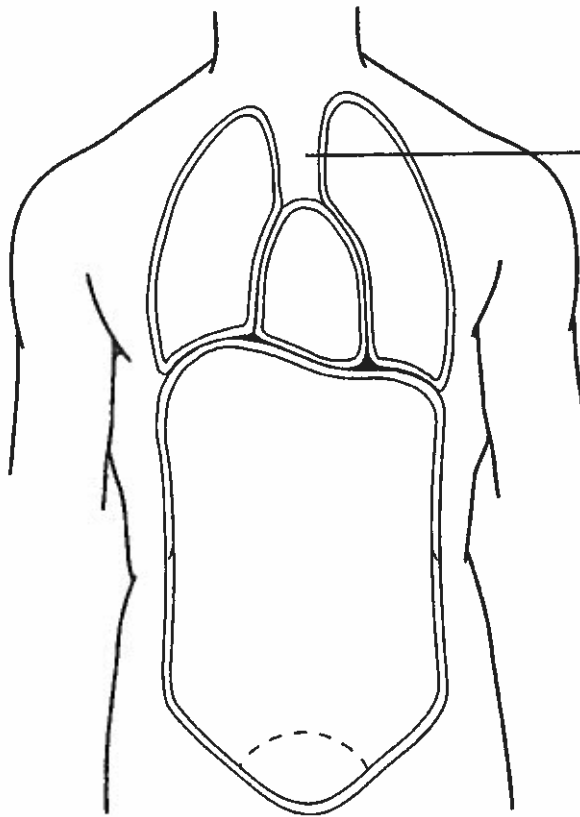


Figure 1.9

7. From the key choices, select the body cavities where the following surgical procedures would occur. Insert the correct answers in the answer blanks. Be precise; select the name of the cavity subdivision if appropriate. *Note: Each question will have 2 answers.*

Key Choices

- | | |
|--------------|-------------|
| A. Abdominal | D. Pelvic |
| B. Cranial | E. Thoracic |
| C. Dorsal | F. Ventral |

- _____ 1. Surgery to remove a cancerous prostate gland
- _____ 2. Coronary artery bypass graft surgery (heart surgery)
- _____ 3. Removal of a brain tumor
- _____ 4. Surgery to remove the distal part of the colon and establish a colostomy
- _____ 5. Gallbladder removal

elbow/the wrist). In each case, choose the structure or organ that matches the given directional term.

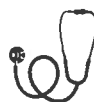- (a) distal: the elbow/the wrist
 - (b) lateral: the hip bone/the umbilicus
 - (c) superior: the nose/the chin
 - (d) anterior: the toes/the heel
 - (e) superficial: the scalp/the skull
6. Assume that the body has been sectioned along three planes: (1) a median plane, (2) a frontal plane, and (3) a transverse plane made at the level of each of the organs listed below. Which organs would be visible in only one or two of these three cases?
 - (a) urinary bladder, (b) brain, (c) lungs, (d) kidneys, (e) small intestine, (f) heart.
 7. Relate each of the following conditions or statements to either the dorsal body cavity or the ventral body cavity.
 - (a) surrounded by the bony skull and the vertebral column
 - (b) includes the thoracic and abdominopelvic cavities
 - (c) contains the brain and spinal cord
 - (d) contains the heart, lungs, and digestive organs
 8. Which of the following relationships is *incorrect*?
 - (a) visceral peritoneum/outer surface of small intestine
 - (b) parietal pericardium/outer surface of heart
 - (c) parietal pleura/wall of thoracic cavity
 9. Which ventral cavity subdivision has no bony protection?
 - (a) thoracic cavity, (b) abdominal cavity, (c) pelvic cavity.
 10. Terms that apply to the backside of the body in the anatomical position include:
 - (a) ventral; anterior
 - (b) back; rear
 - (c) posterior; dorsal
 - (d) medial; lateral

Short Answer Essay Questions

11. According to the principle of complementarity, how does anatomy relate to physiology?
12. Construct a table that lists the 11 systems of the body, names two organs of each system (if appropriate), and describes the overall or major function of each system.
13. List and describe briefly five external factors that must be present or provided to sustain life.
14. Define homeostasis.
15. Compare and contrast the operation of negative and positive feedback mechanisms in maintaining homeostasis. Provide two examples of variables controlled by negative feedback

mechanisms and one example of a process regulated by a positive feedback mechanism.

16. Why is an understanding of the anatomical position important?
17. Define plane and section.
18. Provide the anatomical term that correctly names each of the following body regions: (a) arm, (b) thigh, (c) chest, (d) fingers and toes, (e) anterior aspect of the knee.
19. Use as many directional terms as you can to describe the relationship between the elbow's olecranal region and your palm.
20. (a) Make a diagram showing the nine abdominopelvic regions, and name each region. Name two organs (or parts of organs) that could be located in each of the named regions. (b) Make a similar sketch illustrating how the abdominopelvic cavity may be divided into quadrants, and name each quadrant.



Critical Thinking and Clinical Application Questions

1. John has been suffering agonizing pain with each breath and has been informed by the physician that he has pleurisy. (a) Specifically, what membranes are involved in this condition? (b) What is their usual role in the body? (c) Explain why John's condition is so painful.
2. At the clinic, Harry was told that blood would be drawn from his antecubital region. What body part was Harry asked to hold out? Later, the nurse came in and gave Harry a shot of penicillin in the area just distal to his acromial region. Did Harry take off his shirt or drop his pants to receive the injection? Before Harry left, the nurse noticed that Harry had a nasty bruise on his gluteal region. What part of his body was black and blue?
3. A man is behaving abnormally, and his physician suspects that he has a brain tumor. Which of the following medical imaging techniques would best localize the tumor in the man's brain (and why)? Conventional X ray, DSA, PET, sonography, MRI.
4. Calcium levels in Mr. Gallariani's blood are dropping to dangerously low levels. The hormone PTH is released and soon blood calcium levels begin to rise. Shortly after, PTH release slows. Is this an example of a positive or negative feedback mechanism? What is the initial stimulus? What is the result?
5. Mr. Harvey, a computer programmer, has been complaining of numbness and pain in his right hand. The nurse practitioner diagnosed his problem as carpal tunnel syndrome and prescribed use of a splint. Where will Mr. Harvey apply the splint?